Chinese Journal of Physiology 53(4): 223-233, 2010
DOI: 10.4077/CJP.2010.AMK050

Effects of Shugan-Huayu Powder, A Traditional Chinese Medicine, on Hepatic Fibrosis in Rat Model

Ching-Chang Cheng[1, 2], Nai-Nu Lin[1, 2], Yen-Feng Lee[1, 2], Lung-Yuan Wu[3], Hsiao-Ping Hsu[2], Wen-Jane Lee[1], Kwong-Chung Tung[2, #], and Yung-Tsung Chiu[1, 4, #]

[1]*Department of Education and Research, Taichung Veterans General Hospital, Taichung 40705*
[2]*Departments of Veterinary Medicine, National Chung-Hsing University, Taichung 40227*
[3]*Graduate Institute of Chinese Pharmaceutical Science, China Medical College, Taichung 40402*
and
[4]*Department of Animal Science, National Chung-Hsing University, Taichung 40227, Taiwan, Republic of China*

Abstract

Shugan-Huayu powder (SHP) has been administered to outpatients with chronic liver disease without clear anti-fibrosis mechanism. To investigate the anti-fibrotic effects of SHP on liver fibrosis in a rat model and in hepatic stellate cells (HSCs) *in vitro*, rats were gavaged with CCl_4 at 1.0 g/kg body weight twice a week for 8 weeks to induce liver fibrosis and the rats were randomly assigned to one of the three groups: –CCl_4 alone, low-dose SHP and high-dose SHP. SHP was given by gavages 5 times a week for 8 weeks. Serum, livers and HSCs were assayed for serology, pathology, western blot, zymography and quantitative RT-PCR. Hepatic function improved as decreased serum aspartate aminotransferase and alanine aminotransferase, and collagen deposition and active HSCs were significantly reduced in CCl_4-induced liver by SHP treatment. The expression of matrix metalloproteinase-2 (MMP-2) and transforming growth factor-β1 (*TGF-β1*) mRNA in fibrotic liver showed significant down-regulation after SHP treatment. *In vitro*, inhibition of α-smooth muscle actin (α-SMA) expression and MMP-2 secretion of active HSCs were also noticed by SHP treatment. SHP has an antifibrotic effect on CCl_4-induced liver fibrosis in rats. Anti-fibrotic mechanisms were probably inhibiting activation of HSCs and decreased expression of MMP-2 and TGF-β1.

Key Words: liver fibrosis, traditional Chinese herb, hepatic stellate cell, animal model

Introduction

Liver fibrosis is a common outcome of chronic liver diseases such as alcoholic, viral and autoimmune hepatitis. Abnormal accumulation of extracellular matrix (ECM) proteins, especially collagen types I and III, is the main pathologic feature of liver fibrosis (3). Hepatic stellate cells (HSCs), situated in the space of Disse, have been identified as the major cell type involved in fibrogenesis. During liver fibrogenesis, HSCs undergo activation, a process characterized by increased cell proliferation, morphological transformation into myofibroblast-like cells, increased expression of α-smooth muscle actin (α-SMA) and synthesis of excessive ECM components (9). Moreover, HSCs are able to secrete matrix metalloproteinases (MMPs) which can degrade normal matrix proteins in the extracellular space and stimulate migration of HSCs (12). Down-regulation of MMP-1 and up-regulation of MMP-2 and MMP-9 have been

Corresponding author: Yung-Tsung Chiu, DVM, Ph.D., Department of Education and Research, Taichung Veterans General Hospital, 160, Sec. 3, Taichung Harbor Road, Taichung City 40705, Taiwan, Republic of China. Tel: +886-4-23592525 ext. 4060, Fax: +886-4-23592705, E-mail: ytchiu@vghtc.gov.tw
[#]The contribution of the author, Kwong-Chung Tung, was equal to Yung-Tsung Chiu.
Received: August 19, 2009; Revised: November 20, 2009; Accepted: December 8, 2009.
©2010 by The Chinese Physiological Society and Airiti Press Inc. ISSN : 0304-4920. http://www.cps.org.tw

Table 1. Composition of Shugan-Huayu powder (SHP)

Family	Species[a]	Part used[a]	Components of 28 g SHP (g)
Asteraceae	*Atractylodes macrocephala* Koidz.	Rhizome	3.0
	Carthamus tinctorius L.	Flower	1.0
Cyperaceae	*Cyperus rotundus* L.	Rhizome	4.0
Leguminosae	*Glycyrrhiza uralensis* Fisch.	Rhizome	2.0
Paeoniaceae	*Paeonia Lactiflora* Pall.	Root	4.0
Rosaceae	*Prunus persica* (L.) Batsch.	Seeds	4.0
Rutaceae	*Citrus aurantium* L.	Pericarp	2.0
	Citrus reticulate Blanco.	Pericarp	2.0
Umbelliferae	*Bupleurum chinense* DC.	Rhizome	4.0
	Ligusticum chuanxiong Hort.	Rhizome	2.0

[a]: All plants were purchased from Mainland China and authentized by Wei-Chu, Lee who is the leader of Sheng Chang Pharmaceufical Co., Ltd and by Long-Yuan, Wu, Graduate Institute of Chinese Pharmaceutical Sciences. The authentic samples were stored at Sheng Chang Pharmaceufical Co., Ltd.

observed in patients with liver fibrosis (21). MMP-2 has reportedly been involved in the mitogenic and promigratory effects of reactive oxygen species (ROS) on HSCs (11). The activities of MMPs are inhibited by a family of tissue inhibitors of metalloproteinases (TIMPs) which control the conversion of MMPs from pro-enzymes to the active catalytic form to result in the inhibition of matrix degradation. Notably, TIMP-1 and -2 are the central inhibitors of MMPs (2).

Traditional herbal medicine has been used over thousands of years and is based on experiences and practices. Sho-saiko-to (TJ-9) (27), Inchinko-to (TJ135) (16, 17, 29) and Han-Dan-Gan-Le (20) have been proved to be valuable in treating liver fibrosis. Shugan-huayu powder (SHP) is extracted from ten medicinal herbs. In Taiwan, although SHP is presently the most commonly administered Chinese herbal medicine to outpatients with chronic liver disease, especially those with chronic hepatitis, the mechanism by which SHP works against liver fibrosis is still unknown. In this study, we investigated the anti-fibrotic effects and mechanisms of SHP on carbon tetrachloride (CCl_4)-induced liver fibrosis in a rat model and in *in vitro* in HSC-T6 cells.

Materials and Methods

Preparation of SHP

The SHP, mainly consisting of ten herbs (Table 1), was boiled in hot-water in 50°C and extracted five times with distilled water. The extract was filtered, freeze-dried and stored at 4°C until used. Clinically, SHP was used at a wide range of dosage, 3 to 9 g/day/70 kg for relieving depressed livers, even at a dosage above 20 g/day/70 kg for severe patients based on doctors' experiences. Furthermore, the low dose (0.5 g/kg, 0.1 g/200 g BW rat) used in the study was transferred from the human clinical dosage (5.5 g/70 kg BW) by the index of Body Surface Area (200 g BW rat to 70 kg BW adult human is 0.018). The dried extract was dissolved in water at a concentration of 50 mg/ml as a stock solution. In order to maintain the same treated volume, the high-dose SHP was independently prepared as a five-fold concentration stock solution. Quality control was authorized to Sheng Chang Pharmaceufical Co., Ltd and was analyzed by high-performance liquid chromatography. The concentrations of the major active ingredients in freeze-dried SHP were determined to be the following: hesperidin 6.47 mg/g, naringin 4.50 mg/g, ferulic acid 0.03 mg/g, liquiritin 1.18 mg/g, glycyrrhizin 1.81 mg/g and paeoniflorin 6.66 mg/g.

In Vivo Rat Liver Fibrosis Model

Animals and Treatments

The investigation was conducted in compliance with the Guide for the Care and Use of Laboratory Animals published by the US National Institutes of Health (NIH Publication No. 85-23, revised 1996) and was approved by the Institutional Animal Care and Use Committees of the Taichung Veterans General Hospital. Twenty-four male Sprague-Dawley rats weighting 250-300 g were randomly divided into four groups of six rats each. Group 1 was orally administered olive oil and saline (control group). The other 18 rats were all given l.0 g/kg CCl_4 orally (prepared in 50% CCl_4/olive oil) twice a week for 8 weeks to induce liver fibrosis. Group 2 was treated with CCl_4 and orally administered saline (CCl_4 alone group). Group

3 was treated with CCl_4 and orally administered with low-dose SHP (CCl_4 + SHP 0.5 g/kg group). Group 4 was treated with CCl_4 and orally administered with high-dose of SHP (CCl_4 + SHP 2.5 g/kg group). In order to investigate the preventive effect instead of the therapeutic effect of SHP on liver fibrosis, SHP was given at the same time of CCl_4 administration by gavages 5 times a week for 8 weeks. Three days after the last dose, the rats were anesthetized and sacrificed, blood samples were collected, and liver tissues were removed and weighted. Anterior segment of the removed livers was then excised and stored at -80°C until used for further determination. A portion of the liver was rapidly fixed in 10% neutralized formalin.

Serum Biochemical Measurements

Blood samples for biochemical analysis were collected from the tail vein at the baseline and the end of the third, sixth and eighth week. Blood samples were kept at room temperature for 1 h and centrifuged at 3,500 rpm for 20 min, and the sera were kept at -4°C until further assay. The activity levels of serum aspartate aminotransferase (AST) and alanine aminotransferase (ALT) were analyzed using an automated-analyzer (Hitachi, model 736-60, Tokyo, Japan) to indicate liver injury (14).

Histological Examination

The liver tissues, fixed in 10% formalin, were processed by routine histological procedures. Four-μm paraffin sections were prepared to determine histopathological changes in liver fibrosis induced by CCl_4 administration. The samples were stained either with hematoxylin and eosin for hepatocytic degeneration, or with Sirius red stain for fibrosis scores. The criteria used for scoring fibrosis severity were as follows: 0, normal; 1+, fibrosis present (collagen fiber present that extends from portal triad or central vein to peripheral region); 2+, mild fibrosis (mild collagen fiber present with extension without compartment formation); 3+, moderate fibrosis (moderate collagen fiber present with some pseudo lobe formation); and 4+, severe fibrosis (severe collagen fiber present with thickening of the partial compartments, frequent pseudo lobe formation and bile duct proliferation) (19). The criteria used for scoring hepatocytic degeneration severity were as follows: 0, normal; 1+, focal area; 2+, multifocal area; 3+, locally extensive area; and 4+, diffuse area (26).

Immunohistochemistry

For detection of activated HSCs, α-SMA was assessed immunohistochemically using a specific anti-α-SMA monoclonal antibody by the strepavidin-biotin-peroxidase complex method. Paraffin-embedded sections of each rat liver were deparaffinized in xylene and hydrated in a series of graded alcohol, and subjected to antigen retrieval by microwave at medium power in 0.01 M citrate buffer (pH 6.0). The activity of endogenous peroxidase was blocked with 3% hydrogen peroxide for 10 min. The sections were then incubated with monoclonal anti-α-SMA (Chemicon, Temecula, CA, USA) at 4°C overnight, washed three times with phosphate buffer solution (PBS) between each incubation, and then incubated with goat anti-mouse IgG conjugated with horseradish peroxidase (Santa Cruz Biotech, Santa Cruz, CA, USA). The antigen-antibody complexes were visualized by ABC Immunostain Systems (Santa Cruz Biotech), and exposed to freshly prepared diaminobenzidine (DAB) for 3-5 minutes. Sections were stained lightly with hematoxyline, dehydrated in alcohol series, cleared in xylene, mounted on permount, examined and photographed by light microscopy (Nikon eclipse E800).

Immuno-Fluorescence Staining (α-SMA and MMP-2 Double Staining)

Tissue sections were incubated with a monoclonal mouse anti-human SMA antibody (1:200 dilution, MU128-UC, Biogenex, San Ramon, CA, USA) overnight at 4°C and 1 h at 37°C and then with a rhodamine-conjugated donkey anti-mouse IgG antibody (Jackson ImmunoResearch Laboratories Inc., USA). All the sections were subsequently incubated with goat anti-human MMP-2 antibody (1:200 dilution, SC-8835, Santa Cruz) for 1 h at 37°C and then with fluorescein-conjugated donkey anti-goat IgG antibody (Jackson ImmunoResearch Laboratories Inc., USA) for 1 h at 37°C. All sections were observed under a laser confocal microscopy (TCS-SP2, Leica, Heidelberg, Germany). The pictures of FITC images and those of rhodamine images were merged using the Leica image analysis software.

Western Blot Analysis of α-SMA Expression

Frozen liver tissues (0.1 g) from each rat were homogenized in 1 ml of NP-40 lysis buffer (150 mM NaCl, 50 mM Tris-Cl, pH 7.4, 1% Nonidet P-40) with protease inhibitor (Calbiochem, San Diego, CA, USA). The homogenates were kept on ice for 30 min and then centrifuged at 14,000 ×g for 10 min at 4°C. The supernatants were collected and assayed for protein concentration by Beckman RU-640 spectrophotometer, with bovine serum albumin (BSA) as standards. Aliquot samples were flash-frozen in liquid nitrogen and stored at -80°C. Fifty μg protein from each tissue sample was diluted with PBS and boiled for 5 min. Samples

were electrophoresed on 10% sodium dodecyl sulfate (SDS)-polyacrylamide gels and the proteins were transferred onto Immobilon-PVDF membranes (Millipore, Bedford, MA, USA) in a transfer buffer (6.2 mM boric acid, pH 8.0). The blots were incubated with blocking buffer (1% nonfat milk, 10 mM Tris, 100 mM NaCl, 0.1% Tween 20, 1% BSA) for 1 h at room temperature, and then with specific primary antibody against mouse anti-α-SMA (MU128-UC, Biogenex) or mouse anti-α-tubulin (Santa Cruz), and thereafter diluted (1:1000) with Tris-buffered saline-Tween 20 (TBS-T) containing 1% BSA and 1% nonfat milk. After incubation, the blots were washed with TBS-T for 1 h and incubated with horseradish peroxidase conjugated anti-mouse IgG (Santa Cruz) for 1 h at room temperature. After washing the secondary antibodies (1:5000) with TBS-T, immunoreactive bands were visualized *via* Western blotting detection system (an enhanced chemiluminscence kit, Amersham Pharmacia Biotech, Buckinghamshire, England), and were quantified by image analysis with a Gel-pro Analyzer.

Detection of MMP Activity by Gelatin Zymography

Gelatin zymography, modified as previously described (13), was performed to assess the activities of MMP-2 and MMP-9 in liver tissues. Frozen liver tissue (0.1 g) from each rat was homogenized in 1 ml of PBS buffer and centrifuged at 12,000 rpm for 10 min at 4°C. The supernatants were collected and assayed for protein concentration by the Beckman RU-640 spectrophotometer, with BSA as a standard. Aliquot samples were flash-frozen in liquid nitrogen and stored at -80°C. Twenty μg protein from each tissue sample was diluted with PBS and electrophoresed on 8% SDS-polyacrylamide gels containing 1 mg/ml gelatin. The gels were washed twice with 2.5% Triton X-100 for 30 min, then incubated with reaction buffer (0.01% NaN_3, 40 mM Tris-HCl, pH 8.0 and 10 mM $CaCl_2$) at 37°C for 16 h. The gels were stained with a solution containing 50% methanol, 10% acetic acid and 0.1% Coomassie Brilliant Blue for 10 min, then destained in 10% methanol with 10% acetic acid. The protease bands were quantified by Image Analysis with a Gel-pro Analyzer.

Analysis of Transcripts of TGF-β1 Genes

The mRNA expression levels of *TGF-β1* genes in the liver were analyzed by quantitative real-time reverse transcription polymerase chain reaction (qRT-PCR). Total RNA was isolated by a modified method (14). Briefly, total cellular RNA was extracted from liver tissue using the RNeasy Mini kit (Qiagen GmbH, Hilden, Germany). An aliquot of 1.0 μg of total RNA from each liver sample was subjected to assay using TaqMan One-Step RT-PCR Master Mix Reagent kit, and Applied Biosystems TaqMan Gene Expression Assays pre-designed primers and probes were used: The expression levels of the target gene *TGF-β1* (Assay ID: Rn_00572010_ml) were normalized with the control housekeeping gene, *β-Actin* (Assay ID: Rn01759928_g1) according to the manufacturer's instructions. Real-Time Quantitative RT-PCR was performed on a ABI StepOne Real-Time PCR System (Applied Biosystems, Foster City, CA, USA).

HSC-T6 Cell Lines and In Vitro Assay

Cell Cultures and Cell Viability Assay

The HSC-T6 cell line, a generous gift of Prof. S.L. Friedman, is an immortalized rat HSC cell line transfected by the large T-antigen of SV40 vector containing a Rous sarcoma virus promoter (31). HSC-T6 cells were maintained in Waymouth medium containing 10% FBS, pH 7.0 at 37°C in 5% CO_2.

Alpha-SMA Expression and MMPs Activities in TGF-β1-Treated HSC-T6 Cells

HSCs were seeded in Waymouth medium containing 10% FBS. After 24 h, cells were washed twice with FBS-free Waymouth medium, and replaced by FBS-free Waymouth medium containing TGF-β1 (1 ng/ml) for an hour and washed twice with FBS-free Waymouth medium, then treated with SHP for 24 h, washed with PBS, and collected for the study of α-SMA expression by Western blot analysis or MMPs activities by gelatin-zymography.

Statistical Analysis

All data are expressed as means ± SD. Parametric continuous data between different groups were compared by one-way analysis of variance (ANOVA) followed by Holm-Sidak test. Liver histopathological examination data were analyzed by Kruskal–Wallis nonparametric test. All statistical analysis was conducted using the Scientific Package for the Social Sciences (version 10.1; SPSS, Chicago, IL, USA). A value of $P < 0.05$ (2-tailed) was considered statistically significant.

Results

In Vivo Effects of SHP on CCl_4 Rats

Serum Biochemistry for Hepatic Injury

Baseline levels of serum AST and ALT showed

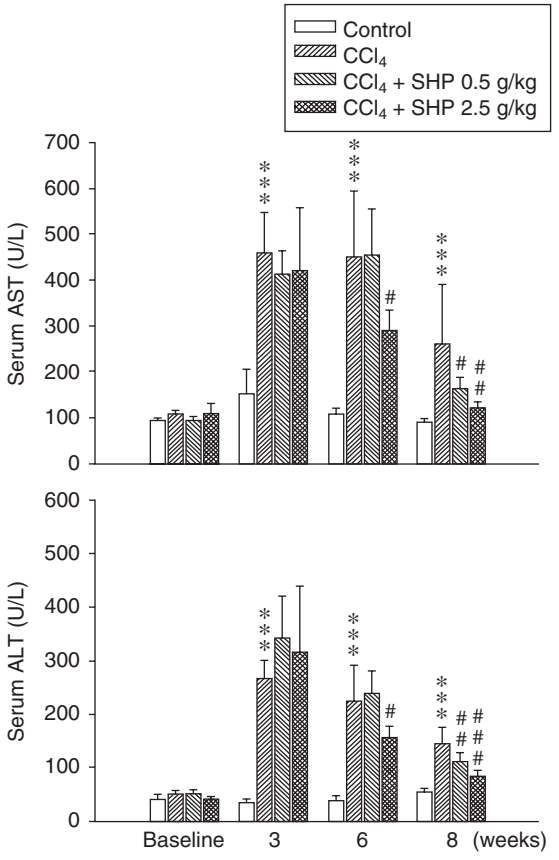

Fig. 1. Effects of SHP on serum AST and ALT activities in CCl_4 rats. Both low-dose and high-dose SHP treatments for 8 weeks ameliorated hepatic injury in CCl_4 rats as indicated by decreases in AST and ALT. Data are means ± SD of six rats. ***: $P < 0.001$ between control and CCl_4 alone groups; #: $P < 0.05$, ##: $P < 0.01$, ###: $P < 0.001$ *vs.* CCl_4 group.

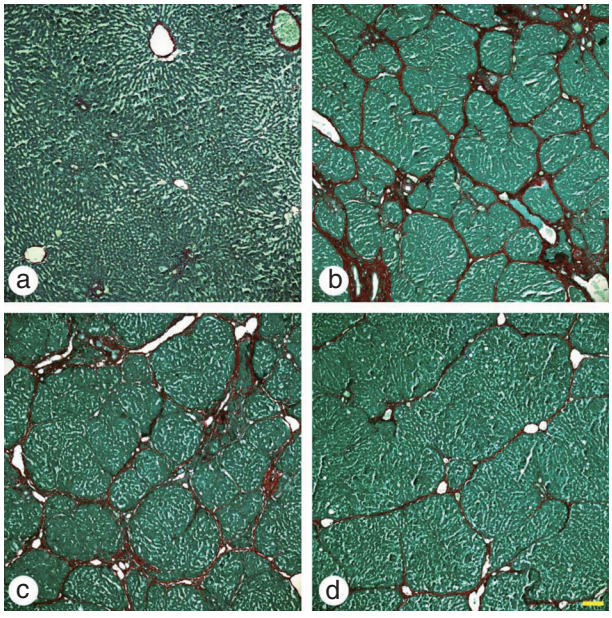

Fig. 2. Representative histological pictures for fibrosis scoring. Histological examination and scoring of liver sections from: (a) Control group; (b) CCl_4-alone group, fibrosis tissue components were accumulated in periportal intralobular, and pericentral region, indicating the characteristics of liver fibrosis; (c) CCl_4 + SHP 0.5 g/kg group; (d) CCl_4 + SHP 2.5 g/kg group. In both (c) and (d), the fibrosis septa became thinner and interrupted indicating that the liver fibrosis was reversed. Sections were stained with Sirius red (Scale bar = 100 μm).

no significant differences between groups. At the third week after the CCl_4 administration, ALT and AST levels were markedly elevated in all three CCl_4-treated groups as compared to the control group ($P < 0.001$), indicating hepatic injury, but no significant difference was found between the CCl_4-alone group and the SHP-treatment groups (Fig. 1). Levels of both ALT and AST in CCl_4 rats were significantly decreased by both low-dose and high-dose SHP treatments for 8 weeks ($P < 0.05$ to 0.001, Fig. 1) suggesting that SHP ameliorated hepatic injury in CCl_4 rats.

Histological Examination and Scoring

The ratio of liver to body weight in CCl_4 group was significant increased as compared to the control group (4.83 ± 0.59 *vs.* 3.21 ± 0.16 %, $P < 0.001$). The liver/BW ratio were decreased in low and high dose SHP treatment groups (4.56 ± 0.54 and 3.89 ± 0.24%), but only significantly decreased in the high-dose SHP treatment group ($P < 0.01$). In the CCl_4 alone group, excessive deposition of collagen with strong Sirius-red staining was observed around the portal area expending central veins to form pseudolobuli (Fig. 2b). In addition, hepatocytic degeneration by hematoxylin and eosin staining was also found from multifocal to locally extensive areas. However, the fibrous septa became thinner and interrupted in both low-dose (Fig. 2c) and high-dose (Fig. 2d) SHP treatment groups. Furthermore, the scores of both hepatic fibrosis and degeneration in SHP-treated groups were significantly reduced in a dose-related fashion as compared to the CCl_4-alone group (Table 2).

Qualitative and Quantitative Expression for α-SMA Protein

We assayed the qualitative expression of α-SMA protein, a marker of HSC activation, in liver sections. Vascular smooth muscle cells were strongly positive for α-SMA, whereas HSCs positive for α-SMA were rarely observed in the control rats (Fig. 3a). In contrast, remarkably increased α-SMA-positive HSCs were detected in centrilobular and periportal areas in CCl_4-alone group (Fig. 3b). However, both low-dose and

Table 2. Histopathological scores of SHP treatment for eight weeks in CCl_4 rats

Group	n	Severity score of liver fibrosis (incidence)[a]						Severity score of hepatic degeneration (incidence)[b]					
		0	1+	2+	3+	4+	Average	0	1+	2+	3+	4+	Average
Control	6	6	0	0	0	0	# #	6	0	0	0	0	# #
CCl_4 alone	6	0	0	0	4	2		0	2	2	1	1	
CCl_4 + SHP 0.5 g/kg	6	0	0	2	4	0		2	4	0	0	0	#
CCl_4 + SHP 2.5 g/kg	6	0	0	3	3	0	#	4	1	1	0	0	#

[a]Data represent the number of rats rated with a given level of liver fibrosis. Categories for liver fibrosis are as follows: 0 = no fibrosis, 1+ = fibrosis present, 2+ = mild fibrosis, 3+ = moderate fibrosis, 4+ = severe fibrosis. See methods for additional details.

[b]Data represent the number of rats rated with a given level of hepatic degeneration. Categories for hepatic degeneration are as follows: 0 = normal, 1+ = focal area, 2+ = multifocal area, 3+ = locally extensive area, 4+ = diffuse area. See methods for additional details.

[#]: $P < 0.05$, [##]: $P < 0.01$ significantly different from CCl_4 alone group.

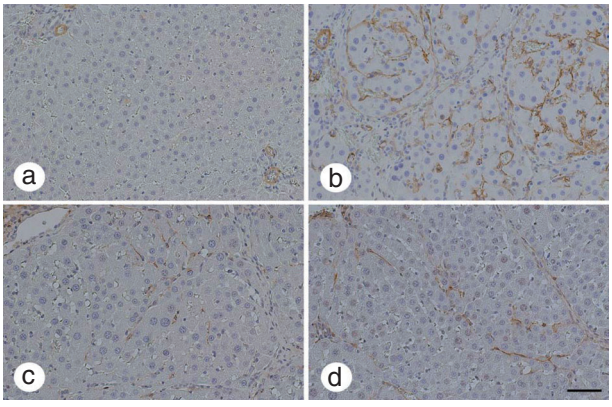

Fig. 3. Expression of α-SMA protein in liver sections of CCl_4 rats by immunochemical staining. (a) Control group, α-SMA stains were strongly positive for vascular smooth muscle cells, but absent in hepatic stellate cells; (b) CCl_4-alone group, many α-SMA positive hepatic stellate cells were migrated into areas of centrilobular and periportal fibrotic bands; (c) CCl_4 + SHP 0.5 g/kg group, and (d) CCl_4 + SHP 2.5 g/kg group, liver sections showed markedly reduced numbers of α-SMA-positive hepatic stellate cells (Scale bar = 50 μm).

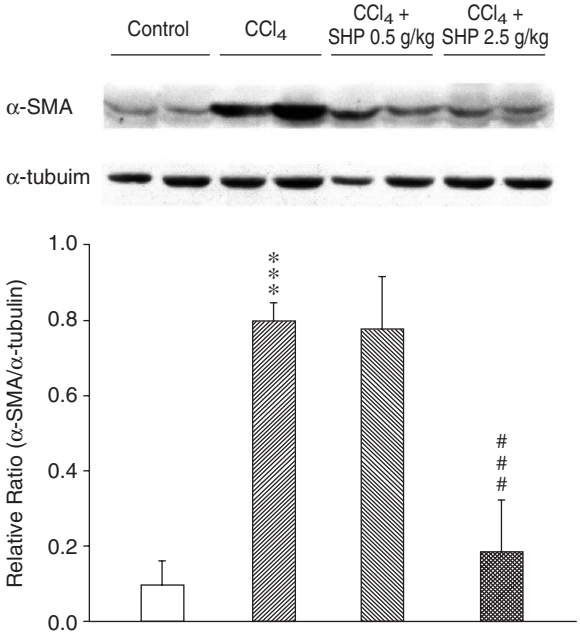

Fig. 4. Quantitative expression of α-SMA protein in CCl_4 rats. The representative pictures of α-SMA and α-tubulin and quantified histograms of Western blotting revealed that high-dose SHP treatment (SHP 2.5 g/kg) significantly inhibited α-SMA expression. Data are means ± SD of six rats. ***: $P < 0.001$ between control and CCl_4 alone groups; ###: $P < 0.001$ *vs*. CCl_4 alone group.

high-dose SHP treatments markedly reduced the numbers of α-SMA-positive HSCs in the livers (Figs. 3c and d). Western blotting experiments also revealed quantitative increase of α-SMA expression in CCl_4-alone group as compared to the control group ($P < 0.001$), while decrease of α-SMA expression was found in high-dose-SHP treatment group ($P < 0.001$, Fig. 4).

Zymography for MMP-2 and MMP-9 Activity

In CCl_4-treated livers, both the proMMP-2 and MMP-2 activities were significantly increased as compared to the control livers in which only the proMMP-2 activity was detected (Fig. 5a). The MMP-9 activity had a similar trend as MMP-2 but was weaker than MMP-2 (Fig. 5a). Both low-dose and high-dose SHP treatments tended to decrease the activities of proMMP-2 and MMP-2 in the liver of CCl_4 rats (Fig. 5b), and the high-dose SHP group showed a significant reduction ($P < 0.05$ and 0.01, Fig. 5b).

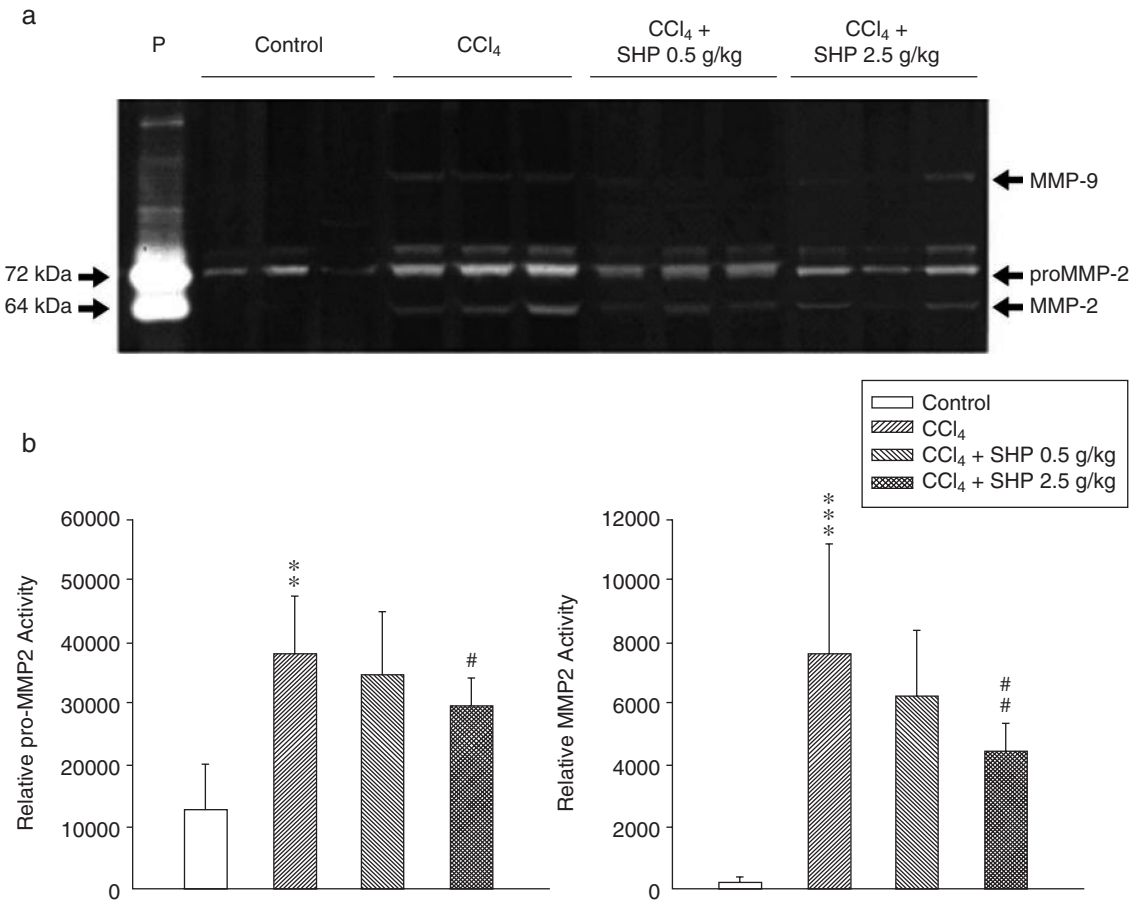

Fig. 5. MMP activities in the livers of CCl_4 rats by gelatin zymography. (a) A representative picture of zymography for MMP-2 activities; (b) Activities of proMMP-2 and MMP-2 levels were analyzed by computerized densitometry. Data are means ± SD of six rats. **: $P < 0.01$, ***: $P < 0.001$ between control and CCl_4 alone groups; #: $P < 0.05$, ##: $P < 0.01$, CCl_4-alone group.

Double Immuno-Fluorescence Staining for α-SMA and MMP-2

In the immuno-staining for α-SMA, α-SMA-positive cells (activated HSCs) were observed in the fibrous septa, portal tracts and sinusoid of livers in CCl_4 rats (Fig. 6b). Most α-SMA-positive HSCs (red) in CCl_4 rats were co-localized with MMP-2 (green) in the merge panel (Fig. 6b, yellow, arrowhead). However, both low-dose (Fig. 6c) and high-dose (Fig. 6d) SHP treatments markedly reduced the number of α-SMA-positive HSCs as shown in Fig. 3, and the MMP-2-positive HSCs in the liver of CCl_4 rats (Figs. 6c and d).

Analysis of TGF-β1 Gene Transcripts by qRT-PCR

There was a significant increase in the mRNA expression level of TGF-β1 ($P < 0.01$) in CCl_4-alone group as compared to the control group (Fig. 7). Both low-dose and high-dose SHP treatments tended to decrease the mRNA expression of *TGF-β1*, and the high-dose SHP group showed a significant reduction ($P < 0.05$, Fig. 7).

In Vitro Effects of SHP on HSC-T6 Cells

Inhibition of α-SMA Expression in TGF-β1-Treated HSC-T6 Cells

The ratio of α-SMA:α-tubulin protein expression was 1.49 ± 0.04 after TGF-β1 (1 ng/ml) stimulation in HSC-T6 cells. This ratio was concentration-dependently reduced to 0.85 ± 0.04 and 0.33 ± 0.03 by the SHP concentration at the range of 50 to 200 μg/ml ($P < 0.001$, Fig. 8). The inhibitory effect of SHP on TGF-β1-treated HSC-T6 cells was not due to its cytotoxicity, as SHP induced cytotoxicity only at concentrations above 2.5 mg/ml.

Inhibition of Cellular MMP-2 Secretion in TGF-β1-Treated HSC-T6 Cells

Only MMP-2 was detectable in the medium and cell lysates of TGF-β1-treated HSC-T6 cells by gelatin

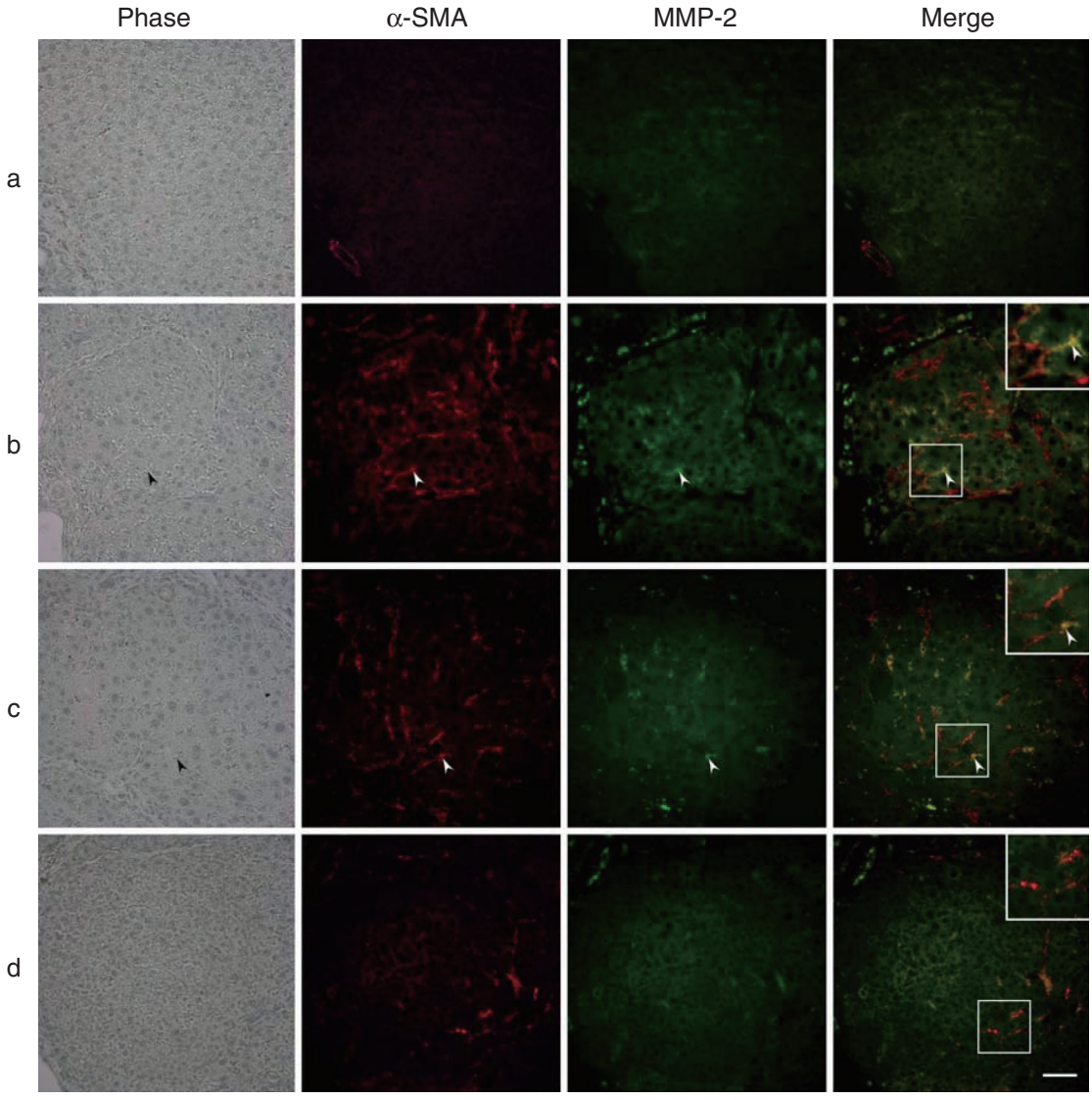

Fig. 6. Double immunofluorescence staining for α-SMA (red) and -MMP-2 (green). (a) Control group, only vascular smooth muscle cells were strongly positive for α-SMA but MMP-2 staining was weak; (b) CCl_4-alone group, many α-SMA positive hepatic stellate cells were migrated into areas of centrilobular and periportal fibrotic bands, and most cells co-localized with MMP-2 in the merge panel (arrow head); (c) CCl_4 + SHP 0.5 g/kg group and (d) CCl_4 + SHP 2.5 g/kg group, with livers showing markedly reduced number of α-SMA-positive hepatic stellate cells and less MMP-2 expression (Scale bar = 50 μm).

zymography. The relative activity of MMP-2 in the medium and HSC-T6 cell lysate were concentration-dependently decreased by SHP administration in TGF-β1-treated HSC-T6 cells (Fig. 9). Secretory MMP-2 (in the medium) was significantly reduced by SHP at concentrations of 100 to 200 μg/ml ($P < 0.01$, 0.001, Fig. 9a), and the MMP-2 expression in HST-T6 cells was also significantly inhibited by SHP at concentrations of 50 to 200 μg/ml ($P < 0.001$, Fig. 9b).

Discussion

In the present study, we observed that the traditional Chinese herbal medicine, SHP, effectively reduced CCl_4-induced rat hepatic fibrosis. The results showed that hepatic fibrosis/degeneration scores, collagen content, mRNA expression of *TGF-β1* gene, protein expression of α-SMA and activity of proMMP-2 and active MMP-2 in CCl_4-induced rats were significantly reduced by SHP treatment. The anti-fibrotic effects of SHP were also confirmed in TGF-β1-treated HSC-T6 cells *in vitro*. Moreover, levels of serum AST and ALT activities in CCl_4-induced rats were reduced by SHP treatment. These findings suggest that SHP exerted anti-fibrotic effects on CCl_4-induced rat liver fibrosis *via* inhibition of HSC activation.

Immunohistostaining analysis showed that activated HSC numbers were decreased by SHP

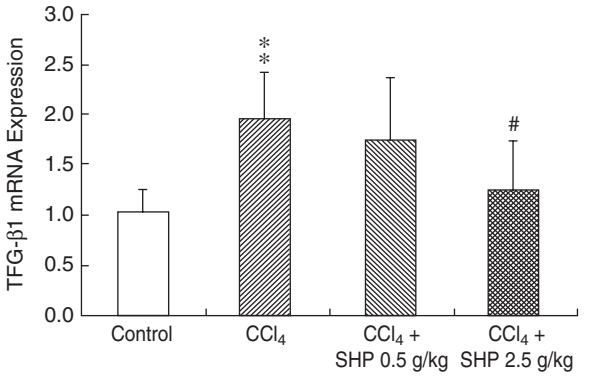

Fig. 7. Effects of SHP treatment on mRNA expression levels of *TGF-β1* genes in CCl_4 rats. Real-time RT-PCR quantifying TGF-β1 gene expression. β-Actin mRNA was used as the control housekeeping gene. Values are means ± SD of six rats. **: $P < 0.01$ between control and CCl_4 alone groups; #: $P < 0.05$ *vs*. CCl_4 group.

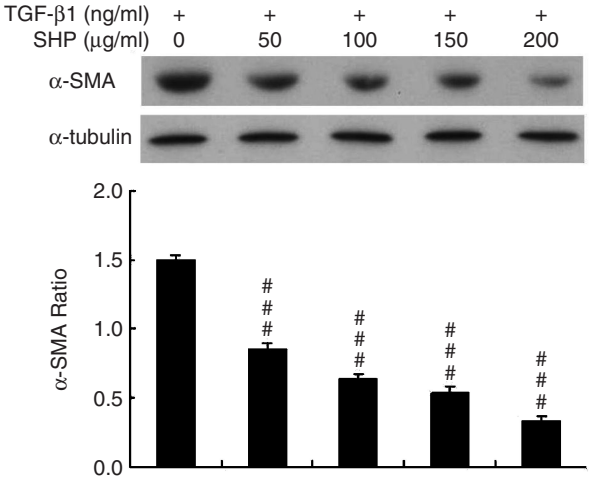

Fig. 8. Quantitative expression of α-SMA protein in TGF-β1-treated HSC-T6 cells. The representative pictures of α-SMA and α-tubulin and quantified histograms of Western blotting revealed concentration-dependent reduction by SHP at the concentration range of 50 to 200 μg/ml medium. Data are means ± SD of three repeats. ###: $P < 0.001$ *vs*. TGF-β1-treated (1 ng/ml) alone HSC-T6 cells.

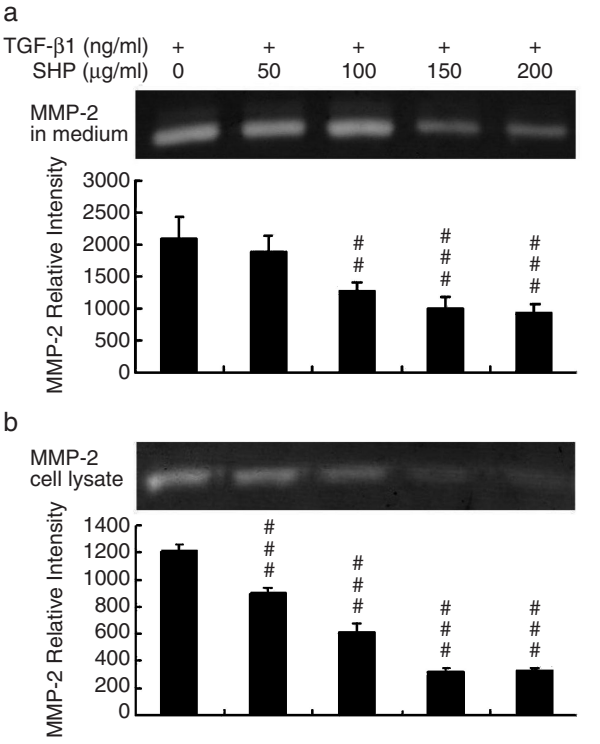

Fig. 9. MMP activities in TGF-β1-treated HSC-T6 cells by gelatin zymography. (a) Relative secretory MMP-2 activities (in the medium) of TGF-β1-treated HSC-T6 cells after SHP treatment, and (b) The MMP-2 activities of TGF-β1-treated HSC-T6 cell lysates were analyzed by computerized densitometry. Data are means ± SD of three repeats. ##: $P < 0.01$, ###: $P < 0.001$ *vs*. TGF-β1-treated alone HSC-T6 cells.

treatment (Figs. 3 and 6). In the injured liver, HSCs are the main cellular source of MMP-2. Active MMP-2 may contribute to disease progression through degradation of normal liver matrix and pro-proliferative effects on HSCs (10), and over-expression of MMP-2 has been demonstrated in the fibrotic liver (1, 6). In this study, we found that proMMP-2 and activated MMP-2 levels were significantly reduced in SHP treatment group as compared to CCl_4 group *in vivo* (Figs. 5 and 6) and TGF-β1-treated HSC-T6 cells *in vitro* (Fig. 9), and this suggests that SHP might down-regulate the mitogenic and proinvasive effects of HSCs.

In experimental and human hepatic fibrosis, expression of TGF-β1 has been found to be strongly increased, and TGF-β1 induced ECM production by HSCs (7). It has been reported that TGF-β1 stimulates collagen synthesis and pro-collagen I mRNA expression in cultured HSCs (4, 7, 8, 25). In the present study, we also found that high-dose SHP treatment significantly reduced mRNA expression of TGF-β1, and SHP treatment also significantly reduced mRNA expression of procollagen I in CCl_4 rats. Although there are as yet no clinically efficacious anti-fibrotic agents, experimental studies have been constantly conducted to assess potentials of agents targeting the reduction of inflammation, inhibition of HSC activation or proliferation, induction of HSC apoptosis, or promotion of scar matrix degradation (8, 24). There are several traditional herbal medicines, including Sho-saiko-to (TJ-9) (28-30), Inchinko-to (TJ135) (16, 17, 29), silymarin (5, 18), *Salvia miltiorrhiza* (15, 22, 23) and Han-Dan-Gan-Le (20) with reported anti-fibrotic effects. In the present study, SHP treatment

resulted in decreased levels of serum AST and ALT (Fig. 1). The results demonstrated that SHP administration had hepato-protective effects in CCl_4-induced rats. Furthermore, SHP treatment led to decreased periportal and bridging fibrosis, and fibrotic septa becoming thinner and interrupted. In addition, the fibrosis score showed a greater improvement in the high-dose SHP group than the CCl_4 group.

In summary, our results showed that an aqueous extract of the traditional Chinese medicine SHP ameliorated CCl_4–induced rat hepatic fibrosis, and the anti-fibrotic effects of SHP were associated with reduction of MMP-2 expression, hepatic collagen content and the number of activated HSCs. These findings might be important in developing a clinically therapeutic strategy for hepatic fibrosis.

Acknowledgments

This work was support by grants from the Taichung Veterans General Hospital (TCVGH-957311B, -967307B) and the Committee on Chinese Medicine and Pharmacy (CCMP95-TP-031).

References

1. Arthur, M.J. Degradation of matrix proteins in liver fibrosis. *Pathol. Res. Pract.* 190: 825-833, 1994.
2. Arthur, M.J., Mann, D.A. and Iredale, J.P. Tissue inhibitors of matrix metalloproteinase, hepatic stellate cells and liver fibrosis. *J. Gastroenterol. Hepatol.* (13 Suppl): S33-S38, 1998.
3. Benyon, R.C. and Arthur, M.J. Extracellular matrix degradation and the role of hepatic stellate cells. *Semin. Liver Dis.* 21: 373-384, 2001.
4. Bissell, D.M., Roulot, D. and George, J. Transforming growth factor β and the liver. *Hepatology* 34: 859-867, 2001.
5. Boigk, G., Stroedter, L., Herbst, H., Waldschmidt, J., Riecken, E.O. and Schuppan, D. Silymarin retards collagen accumulation in early and advanced biliary fibrosis secondary to complete bile duct obliteration in rats. *Hepatology* 26: 643-649, 1997.
6. Burt, A.D. Cellular and molecular aspects of hepatic fibrosis. *J. Pathol.* 170: 105-114, 1993.
7. Friedman, S.L. Molecular regulation of hepatic fibrosis, an intergrated cellular response to tissue injury. *J. Biol. Chem.* 275: 2247-2250, 2000.
8. Friedman, S.L. Liver fibrosis-from bench to bedside. *J. Hepatol.* 38 (1 Suppl): S38-S53, 2003.
9. Friedman, S.L. Mechanisms of hepatic fibrogenesis. *Gastroenterology* 134: 1655-1669, 2008.
10. Friedman, S.L., Roll, F.J., Boyles, J., Arenson, D.M. and Bissell, D.M. Maintenance of differentiated phenotype of cultured rat hepatic lipocytes by basement membrane matrix. *J. Biol. Chem.* 264: 10756-10762, 1989.
11. Galli, A., Svegliati-Baroni, G., Ceni, E., Milani, S., Ridolfi, F., Salzano, R., Tarocchi, M., Grappone, C., Pellegrini, G., Benedetti, A., Surrenti, C. and Casini, A. Oxidative stress stimulates proliferation and invasiveness of hepatic stellate cells *via* a MMP2-mediated mechanism. *Hepatology* 41: 1074-1084, 2005.
12. Gressner, A.M. Mediators of hepatic fibrogenesis. *Hepatogastroenterology* 43: 92-103, 1996.
13. Heussen, C. and Dowdle, E.B. Electrophoretic analysis of plasminogen activators in polyacrylamide gels containing sodium dodecyl sulfate and copolymerized substrates. *Anal. Biochem.* 102: 196-202, 1980.
14. Hsu, Y.C., Chiu, Y.T., Lee, C.Y., Lin, Y.L. and Huang, Y.T. Increases in fibrosis-related gene transcripts in livers of dimethylnitrosamine-intoxicated rats. *J. Biomed. Sci.* 11: 408-417, 2004.
15. Hsu, Y.C., Lin, Y.L., Chiu, Y.T., Shiao, M.S., Lee, C.Y. and Huang, Y.T. Anti-fibrotic effects of Salvia miltiorrhiza on dimethylnitrosamine-intoxicated rats. *J. Biomed. Sci.* 12: 185-195, 2005.
16. Imanishi, Y., Maeda, N., Matsui, H., Takashima, T., Seki, S., Arakawa, T. and Kawada, N. Suppression of rat stellate cell activation and liver fibrosis by a Japanese herbal medicine, Inchinko-to (TJ135). *Comp. Hepatol.* 3 (Suppl 1): S1-S11, 2004.
17. Inao, M., Mochida, S., Matsui, A., Eguchi, Y., Yulutuz, Y., Wang, Y., Naiki, K., Kakinuma, T., Fujimori, K., Nagoshi, S. and Fujiwara, K. Japanese herbal medicine Inchin-ko-to as a therapeutic drug for liver fibrosis. *J. Hepatol.* 41: 584-591, 2004.
18. Jia, J.D., Bauer, M., Cho, J.J., Ruehl, M., Milani, S., Boigk, G., Riecken, E.O. and Schuppan, D. Antifibrotic effect of silymarin in rat secondary biliary fibrosis is mediated by downregulation of procollagen alpha1(I) and TIMP-1. *J. Hepatol.* 35: 392-398, 2001.
19. Jonker, A.M., Dijkhuism F.W.J., Boes, A., Hardonk, M.J. and Grond, J. Immunohistochemical study of extracellular matrix in acute galactosamine hepatitis in rats. *Hepatology* 15: 423-431, 1992.
20. Li, C., Luo, J., Li, L., Cheng, M., Huang, N., Liu, J. and Waalkes, M.P. The collagenolytic effects of the traditional Chinese medicine preparation, Han-Dan-Gan-Le, contribute to reversal of chemical-induced liver fibrosis in rats. *Life Sci.* 72: 1563-1571, 2003.
21. Milani, S., Herbst, H., Schuppan, D., Grappone, C., Pellegrini, G., Pinzani, M. and Casini, A. Differential expression of matrix-metalloproteinase-1 and -2 genes in normal and fibrotic human liver. *Am. J. Pathol.* 144: 528-537, 1994.
22. Nan, J.X., Park, E.J., Kang, H.C., Park, P.H., Kim, J.Y. and Sohn, D.H. Anti-fibrotic effects of a hot-water extract from Salvia miltiorrhiza roots on liver fibrosis induced by biliary obstruction in rats. *J. Pharm. Pharmacol.* 53: 197-204, 2001.
23. Oh, S.H., Nan, J.X., Sohn, D.W., Kim, Y.C. and Lee, B.H. Salvia miltiorrhiza inhibits biliary obstruction-induced hepatocyte apoptosis by cytoplasmic sequestration of p53. *Toxicol. Appl. Pharmacol.* 182: 27-33, 2002.
24. Poli, G. Pathogenesis of liver fibrosis: role of oxidative stress. *Mol. Aspects Med.* 21: 49-98, 2000.
25. Rojkind, M. and Greenwel, P. Pathophysiology of liver fibrosis. In: The Liver, Biology and Pathobiology, fourth ed., edited by Arias, I.M., Boyer, J.L., Chisari, F.V., Fausto, N., Schachter, D. and Shafritz, D.A. Philadelphia, Lippincott Williams & Wilkins, 2001, pp. 721-738.
26. Ruwart, M.J., Wilkinson, K.F. and Rush, B.D. The integrated value of serum procollagen III peptide over time predicts hepatic hydroxyproline content and stainable collagen in a model of dietary cirrhosis in the rat. *Hepatology* 10: 801-806, 1989.
27. Sakaida, I., Hironaka, K., Kimura, T., Terai, S., Yamasaki, T. and Okita, K. Herbal medicine Sho-saiko-to (TJ-9) increases expression matrix metalloproteinases (MMPs) with reduced expression of tissue inhibitor of metalloproteinases (TIMPs) in rat stellate cell. *Life Sci.* 74: 2251-2263, 2004.
28. Sakaida, I., Matsumura, Y., Akiyama, S., Hayashi, K., Ishige, A. and Okita, K. Herbal medicine Sho-saiko-to (TJ-9) prevents liver fibrosis and enzyme-altered lesions in rat liver cirrhosis induced by a choline-deficient L-amino acid-deficient diet. *J. Hepatol.* 28: 298-306, 1998.
29. Sakaida, I., Tsuchiya, M., Kawaguchi, K., Kimura, T., Terai, S. and Okita, K. Herbal medicine Inchin-ko-to (TJ-135) prevents liver fibrosis and enzyme-altered lesions in rat liver cirrhosis induced by a choline-deficient L-amino acid-deficient diet. *J. Hepatol.* 38: 762-769, 2003.

30. Shimizu, I., Ma, Y.R., Mizobuchi, Y., Liu, F., Miura, T., Nakai, Y., Yasuda, M., Shiba, M., Horie, T., Amagaya, S., Kawada, N., Hori, H. and Ito, S. Effects of Sho-saiko-to, a Japanese herbal medicine, on hepatic fibrosis in rats. *Hepatology* 29: 149-160, 1999.

31. Vogel, S., Piantedosi, R., Frank, J., Lalazar, A., Rockey, D.C., Friedman, S.L. and Blaner, W.S. An immortalized rat liver stellate cell line (HSC-T6): a new cell model for the study of retinoid metabolism *in vitro*. *J. Lipid Res.* 41: 882-893, 2000.