Chinese Journal of Physiology 58(×): ×××-×××, 2015
DOI: 10.4077/CJP.2015.BAD339

Hepatoprotective Effects of Traditional Chinese Medicine on Liver Fibrosis from Ethanol Administration following Partial Hepatectomy

Jia-Ping Wu[1, *], Tsung-Jung Ho[2, 3, *], Chin-Chuan Tsai[4, 5], Yu-Lan Yeh[6, 7], Chien-Chung Lin[8], Kuan-Ho Lin[9], Dennis Jine-Yuan Hsieh[10, 11], Li-Mien Chen[12], Lung-Fa Pan[13], and Chih-Yang Huang[1, 2, 14]

[1]*Graduate Institute of Basic Medical Science, China Medical University, Taichung 40402*
[2]*School of Chinese Medicine, China Medical University, Taichung 40402*
[3]*Chinese Medicine Department, China Medical University Beigang Hospital, Beigang, Yunlin 65152*
[4]*School of Chinese Medicine for Post-Baccalaureate, I-Shou University, Kaohsiung 84001*
[5]*Chinese Medicine Department, E-Da Hospital, Kaohsiung 82445*
[6]*Department of pathology, Changhua Christian Hospital, Changhua 50006*
[7]*Department of Medical Technology, Jen-Teh Junior College of Medicine, Nursing and Management, Miaoli 35664*
[8]*Orthopaedic Department, Armed Forces General Hospital, Taichung 32551*
[9]*Emergency Department, China Medical University Hospital, Taichung 40447*
[10]*School of Medical Laboratory and Biotechnology, Chung Shan Medical University, Taichung 40201*
[11]*Department of Clinical Laboratory, Chung Shan Medical University Hospital, Taichung 40201*
[12]*Center of General Education, Central Taiwan University of Science & Technology, Taichung 40601*
[13]*Department of Medical Imaging and Radiological Sciences of Central Taiwan University of Science and Technology, Taichung 40601*
and
[14]*Department of Health and Nutrition Biotechnology, Asia University, Taichung 41354*
Taiwan, Republic of China

Abstract

The aim of this study was to establish the effective hepatoprotective properties of traditional Chinese medicines in fibrotic rat liver regeneration after partial hepatectomy (PHx). Fibrosis was induced in rats by ethanol (EtOH, 5 ml/kg) administration for 6, 24, 72, and 168 h. The rats were then fed four traditional Chinese medicines (1g/kg/day, *Codonopsis pilosula* (CP), *Salvia miltorrhiza Bunge* (SMB), *Bupleurum kasi* (BK), and *Elephantopus scaber L* (ESL) to Spraque-Dawley rats for 6, 24, 72 and 168 h, respectively. Surgical 70% cirrhotic fibrosis PHx was then conducted at 6, 24, 72 and 168 h. The effects on liver regeneration were examined to estimate and measure HGF, FAK, Cyclin D1, Cyclin E, and pRb protein expression using western blotting analysis. Cyclin D1, MMP-2, MMP-9, TIMP-1, TIMP-2 and TIMP-3 mRNA by RT-PCR were analyzed in cirrhotic fibrosis rats. TGF-β1, Cyclin D1, Cyclin E, pRb and E2F mRNA expression levels were determined in fibrotic rats following PHx using RT-PCR. We found elevated GOT, GPT, ALP, γ-GT, GSH, NPSH and total- bilirubin in serum after 6 h ethanol administration. These levels were progressively decreased over 168 h. Total protein and albumin were reduced in serum after 6 h administration and then progressively increased. In contrast, tissues disorder histology and morphology were determined in liver sections. After rats were fed traditional Chinese medicines we found that SMB extraction not only induced HGF, FAK, Cyclin D1, and pRb protein expression and Cyclin D1 mRNA increases, but also reduced MMP-2 and MMP-9 after 24 and

Corresponding author: Dr. Chih-Yang Huang, Graduate Institute of Basic Medical Science, China Medical University, Taichung 40402, Taiwan, R.O.C. Tel: +886-4-22053366 ext. 3313, Fax: +886-4-22051276, E-mail: cyhuang@mail.cmu.edu.tw
*Jia-Ping Wu and Tsung-Jung Ho are equally contributed to this work.
Received: December 15, 2014; Revised: February 24, 2015; Accepted: March 5, 2015.

72 h post injury. In the cell cycle S phase the Cyclin E protein expression was increased by ESL. CP induced TIMP-1, TIMP-2 and TIMP-3 mRNA increases in fibrotic rats. We detected liver regeneration in fibrotic rats. We also found that the liver regeneration index increased from 6 to 168 h post PH. After 168 h fibrotic liver regeneration rats exhibited reduced TGF-β1 mRNA expression and enhanced Cyclin D1, Cyclin E, pRb and E2F mRNA expression. TCMs play a crucial role in the early mediating process in fibrotic rat liver regeneration after PHx.

Key Words: fibrotic, hepatocyte growth factor, liver regeneration, partial hepatectomy, traditional Chinese medicine

Introduction

Traditional Chinese medicines are currently the world's most effective treatment for liver disease. They have shown positive effects in treating nearly every known form of liver disease including fibrosis, cirrhosis, hepatitis, necroses. That is why they are used today. Almost all liver damage occurs due to drug and alcohol abuse. Some reports have indicated that Traditional Chinese Medicines also help prevent liver disease from occurring (1, 2). This study examined whether Traditional Chinese Medicines can protect the liver during major hepatectomy and ensure that the partial liver remnant is able to maintain sufficient function or not. We think Traditional Chinese Medicines could be applied as an anti-carcinogen and as a supportive treatment for liver damage from liver resection (3). When the liver undergoes surgical resection or suffers toxic injury, hepatocytes will start to regenerate using a compensatory growth process and then return to the non-proliferative state (4, 5, 9). However, much of the research into hepatic growth mechanisms has been performed using partial hepatectomy (PHx) animal models (4). Most liver cancer patients require partial liver section through surgery. After surgery the liver needs to grow to maintain liver mass (6). If the native hepatocyte proliferation function cannot be maintained the whole liver function integration after PHx will fail. Much of hepatic liver regeneration growth drug studies have been performed using partial hepatectomy (PHx) (7). This study focused on traditional chinese medicines acting as hepatoprotective herbal agents in facilitating cell protection progress in fibrosis liver regeneration.

Salvia miltorrhiza Bunge (SMB) is a widely used traditional Chinese herb in China. Some reports demonstrated that SMB promotes blood flow, removes blood stasis, stimulates cell survival signals, improves cell cycle control (8), inhibits cytokine inflammation (9) and improves anti-scar formation (10). It has been long used for treating liver disease in China. *Codonopsis pilosula* (CP) and *Bupleurum kasi* (BK) are important traditional Chinese crude drugs for treating hepatitis malaria and intermittent fever to resist cytokine and anti-fibrosis levels (11). *Elephantopus scaber L.* (ESL) is a folk medicine from Taiwan derived from the entire *Elephantopus scaber L.* E mollis H.B.K. and Pseudoelephantopus spicatos (Jass) plants. Rohr has hepatoprotective effects (12), anticancer effects on various cancer cells and induces cancer cell apoptosis from cell cycle arrest (13).

Growth factors (HGF, TGF-β1) regulate the liver regeneration process by providing both stimulatory and inhibitory signals for cell proliferation. Hepatocyte growth factor (HGF) will immediately stimulate the cell cycle and DNA synthesis when there are major changes in the complete mitogen expression for hepatocytes. PHx induces hepatocytes in the expression of a relatively large number of genes in the cell cycle (14), especially in extensive remodeling of the hepatic extracellular matrix, which occurs shortly after PHx. HGF is believed to play a primary role in liver regeneration by promoting cell proliferation, survival and morphogenesis through regulated DNA synthesis.

Materials and Methods

Animals and Ethanol (EtOH) Treatments

Male Spraque-Dawley rats were obtained from the National Science Council in Taiwan. Rats were acclimated for 1 week prior to the beginning of all experiments. Rats were oral administered with ethanol (EtOH, 5 ml/kg, 20%) one day once, for 6, 24, 72, and 168 h. Rats were obtained ethanol induced fibrotic liver rats and then performed 70% PHx for regeneration at 6, 24, 72 and 168 h, and then fed four traditional Chinese medicines (1 g/kg/day, *Codonopsis pilosula* (CP), *Salvia miltiorrhiza Bunge* (SMB), *Bupleurum kasi* (BK), and *Elephantopus scaber L* (ESL) for 6, 24, 72 and 168 h to male Spraque-Dawley rats.

Experimental the Fibrotic Rats Partial Hepatectomy (PHx)

Fibrotic livers induced by ethanol were subjected to 70% PHx. All of the surgical operations were performed the same. Ketamine was injected subcutaneously at a dose of 30 mg/kg. The liver resections consisted of removing 70% of the fibrotic liver mass. The

Table 1. The primer pair sequences were used by RT-PCR

Primers	Sequence	Tm	Length (bp)
Cyclin D1		45°C	480 bp
Forward primer	5'-AGGAGACCATTCCCCTGACT-3'		
Reverse primer	5'-TTCTTCCTCCACTTCCCCTT-3'		
Cyclin E		59°C	500 bp
Forward primer	5'-ACCTACAGTGAAGATGCACACC-3'		
Reverse primer	5'-CCTGTAGTTCTTGTTTCCTGCAC-3'		
pRb		48°C	470 bp
Forward primer	5'-AGGAGGACTGTTCTCTAAGG-3'		
Reverse primer	5'-GAGTGAGGTGTGTCTTCTGA-3'		
E2F		50°C	500 bp
Forward primer	5'-AACATCCAGAACATCCAGTGGGTAGGCAG-3'		
Reverse primer	5'-GGCTGTCAGTAGCCTCCAAG-3'		
MMP2		60°C	450 bp
Forward primer	5'-CACCCCTGGCATCTTCTCCTT-3'		
Reverse primer	5'-AGCGTCTTCAGAGACAGCCAG-3'		
MMP9		56°C	480 bp
Forward primer	5'-TAAGACTCACCTGGGTACTG-3'		
Reverse primer	5'-GCATGTAGTCACTCTTCACC-3'		
TGFβ1		45°C	450 bp
Forward primer	5'-ACAGCACGCTTGTGGAT-3'		
Reverse primer	5'-GTCTTCAAGCAAGAGGACCA-3'		
GAPDH		45°C	450 bp
Forward primer	5'-GGGTGTGAACCACGAGAAAT-3'		
Reverse primer	5'-CCACAGTCTTCTGAGTGGCA-3'		

livers were collected at 6, 24, 72, and 168 h time points after the hepatectomy. The postoperative regenerating livers were excised and washed in PBS, then immediately frozen in liquid nitrogen.

Hot-Water Extract Traditional Chinese Medicine Preparation

Codonopsis pilosula (CP), *Salvia miltiorrhizae Bunge* (SMB), *Buplearum kaoi* (BK), *Elephantopus scaber L* (ESL) were extracted by boiling with distilled water for 1 h. The extraction was filtered, freeze-dried and kept at 4°C. The dried extract was dissolved in distilled water before use.

Western Blot

Remnant and regeneration proteins were separated using 12.5% SDS-PAGE and then transferred to PVDF. Membranes were blocked in 5% milk (diluted in Tris-buffered saline and 0.1% Tween 20) and incubated with the appropriate primary antibodies (HGF, FAK, cyclin D1, cyclin E, pRb) at 4°C overnight. HRP anti-IgG was used as the secondary reagent. After extensive washing the targeted proteins were detected using enhanced chemiluminescence (ECL).

Reverse Transcriptase PCR (RT-PCR)

For RT-PCR analysis, total RNA derived from liver homogenized tissues. The first-strand synthesis was applied according to the manufacturer's instructions. PCR primers were used as shown in Table 1. 1 μg of total RNA was performed with a reverse transcription reaction and reverse transcriptase. The cDNA was amplified using Tag DNA polymerase. The initial step was denatured at 95°C, 1 min then with 35 cycles of denaturation at 95°C for 30 s, annealed at 50-60°C for 40 s, and elongation at 72°C for 2 min. The final extension at 72°C for 10 min was applied to all reactions. The RT-PCR results were analyzed based on the following electrophoresis on 1.5% (w/v) agarose gel containing 0.5 μg/ml ethidium bromide.

Statistical Analysis

All data examined were expressed as mean ±

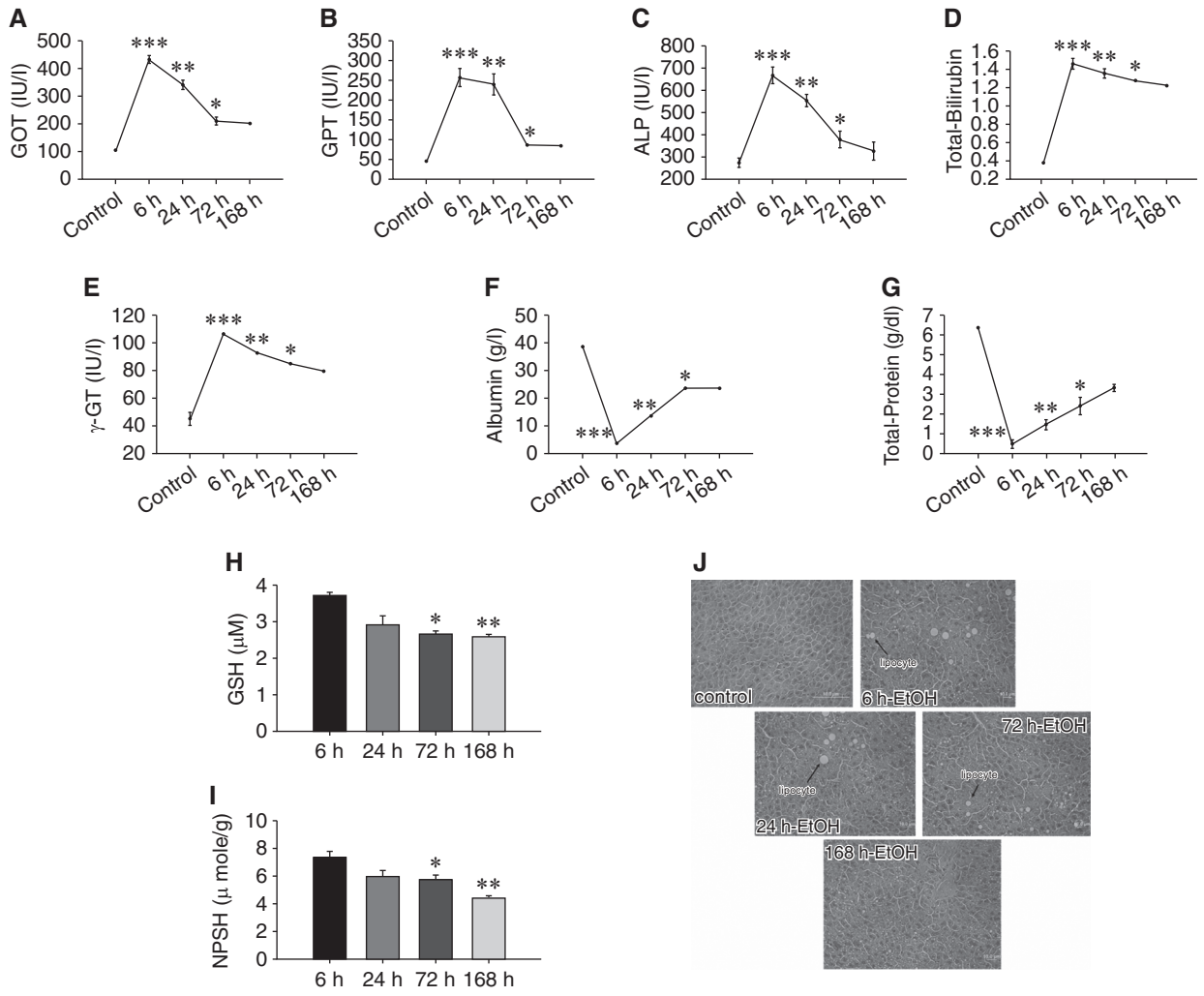

Fig. 1. Establishment of liver fibrosis in rats. Biochemistry function of liver. GOT (A). GPT (B). ALP (C). total-bilibrubin (D). γ-GT (E). Albumin (F). total-protein (G). GSH (H). NPSH (I). photomicrographs of fibrotic rat livers (J). Quantification of densitometry analysis of protein levels. All data are presented as means ± SD (n = 6) *$P < 0.05$, **$P < 0.01$, ***$P < 0.001$, significant difference compared with the corresponding control group.

standard deviation (SD). For Western blot and analysis, quantitation was carried out by scanning and analyzing the intensity of the hybridization signals using the FUJIFILM Imagine program. Statistical data analysis was performed using SigmaStat software. Comparison between groups was made using two way ANOVA test followed by the *post-hoc* test for equality of variances. A P value of less than 0.05, 0.01 and 0.001 were considered to be statistically significant.

Results

Establishment of the Fibrotic Animal Model with Ethanol (EtOH)-Induced Hepatic Damage in Rats

Ethanol (EtOH, 5ml/kg) causes liver injury when administered to normal rats. Serum biochemical values were administered sterile saline (normal) and EtOH, results as Fig. 1. Rats receiving EtOH treatment exhibited a significant increase in some biomarkers and pathological findings. Elevations in glutamyl oxaloacetic transaminase (GOT), glutamyl pyrubic transaminase (GPT), Alkaline phosphatase (ALP), Gamma-Glutamyl Transpeptidace (γ-GT) and total-bilirubin activities and reductions in albumin and total-protein in serum were observed ($P < 0.05$, $P < 0.01$, $P < 0.001$ significantly different compared with the control). Liver biological function markers, glutathione (GSH) and nonprotein sulfhydryl (NPSH), were also increased at 24 h ($P < 0.01$) and then decreased at 72 ($P < 0.05$) and 168 h ($P < 0.05$). After treatment all biological markers increased temporarily at 6 h and then decreased until EtOH withdrawal. In contrast we also observed the histology and morphology of liver sections were disordered (Fig. 1J).

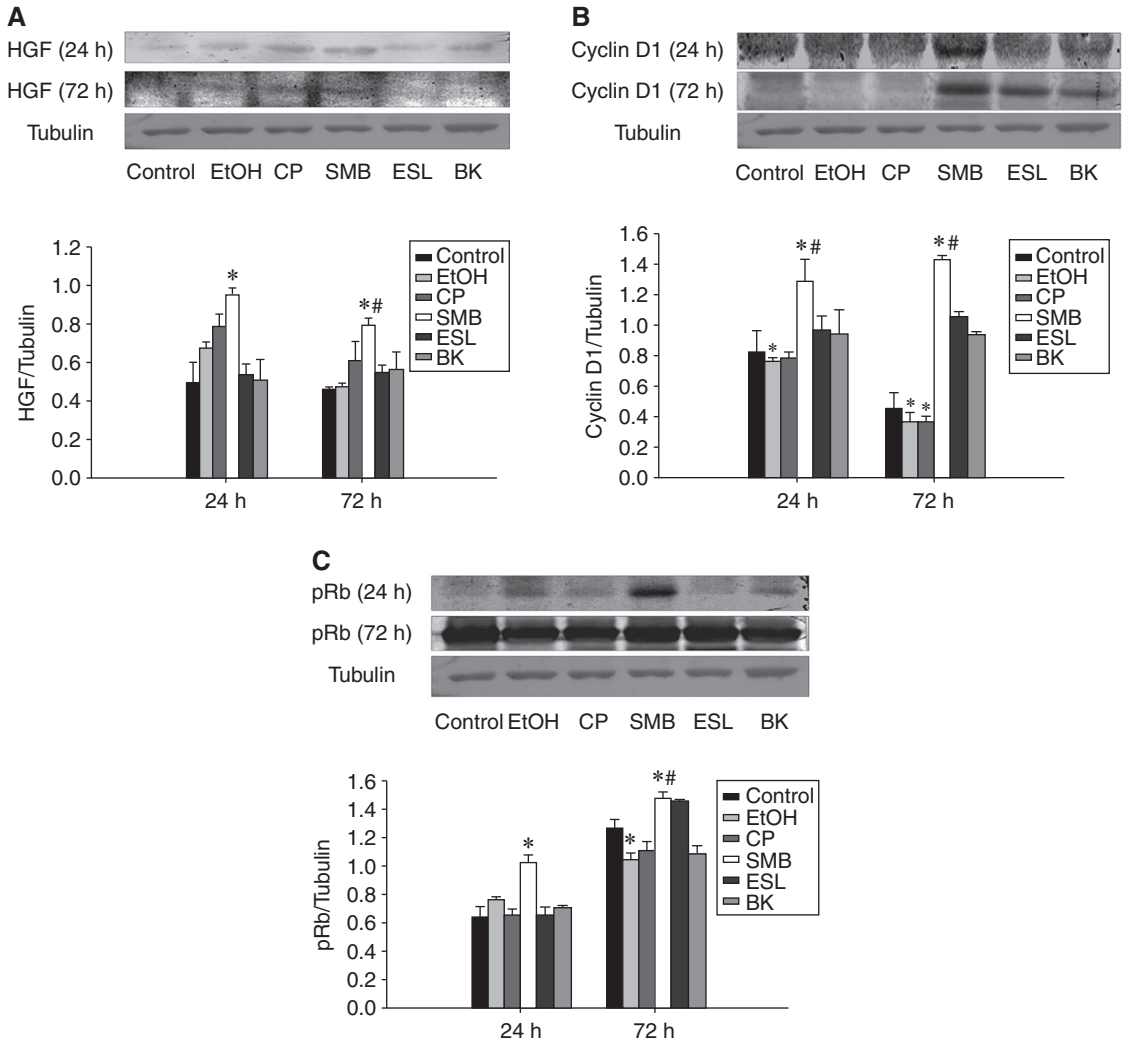

Fig. 2. A traditional Chinese medicine, *Salvia miltorrhiza Bunge* (SMB), effects on fibrotic rat after 24 and 72 h ethanol-treated. Western blotting analysis of HGF (A), Cyclin D1 (B), and pRb (C) expression levels by Traditional Chinese medicines including *Codonopsis pilosula* (CP), *Bupleurum kasi* (BK), *Elephantopus scaber L.* (ESL), and *Salvia miltorrhiza Bunge* (SMB). Equal amounts of lysate were separated by 12.5% SDS-PAGE. Quantification of densitometry analysis of protein levels. All data are presented as means ± SD (n = 6) $*P < 0.05$, significant difference compared with the corresponding control group. $^{\#}P < 0.05$, significant difference compared with EtOH group.

Fibrotic Rats Treated with TCMs Accelerate Liver Regeneration Signals

We detected the traditional Chinese medicine's role in the toxic injury process in rats. The molecular mechanisms of Hepatocyte growth factor (HGF), Focal Adhesion Kinase (FAK), Cyclin D1, and retinoblastoma protein (pRb) protein expression in TCM treatment after ethanol administration at 24 and 72 h were examined ($P < 0.05$). We found that the traditional Chinese medicine, *Salvia miltiorrhizae Bunge* (SMB), improved HGF, FAK, Cyclin D1, and pRb protein expression after ethanol administration toxicity injury at 24 and 72 h. Moreover, the results showed that HGF, FAK, Cyclin D1 and pRb expression declined after oral administration ethanol 24 and 72 h ($P < 0.05$) (Figs. 2 and 3). We also detected G1 phase checkpoints, Cyclin D1, mRNA expression levels. Fig. 3A, shows that Cyclin D1 mRNA expression was also increased by *Salvia miltiorrhizae Bunge* (SMB) ($P < 0.05$). We determined that *Salvia miltiorrhizae Bunge* (SMB) protected against liver injury after ethanol administration at 24 and 72 h. It went without saying that HGF, FAK, Cyclin D1, Cyclin E and pRb expression decreased from ethanol injury. Interestingly, we did not find Cyclin Eexpression increased by *Salvia miltiorrhizae Bunge* (SMB) after ethanol injury at 24 and 72 h ($P < 0.05$). However, we could find that a traditional Chinese medicine, *Elephantopus scaber L.* (ESL), induced Cyclin E expression after ethanol injury at

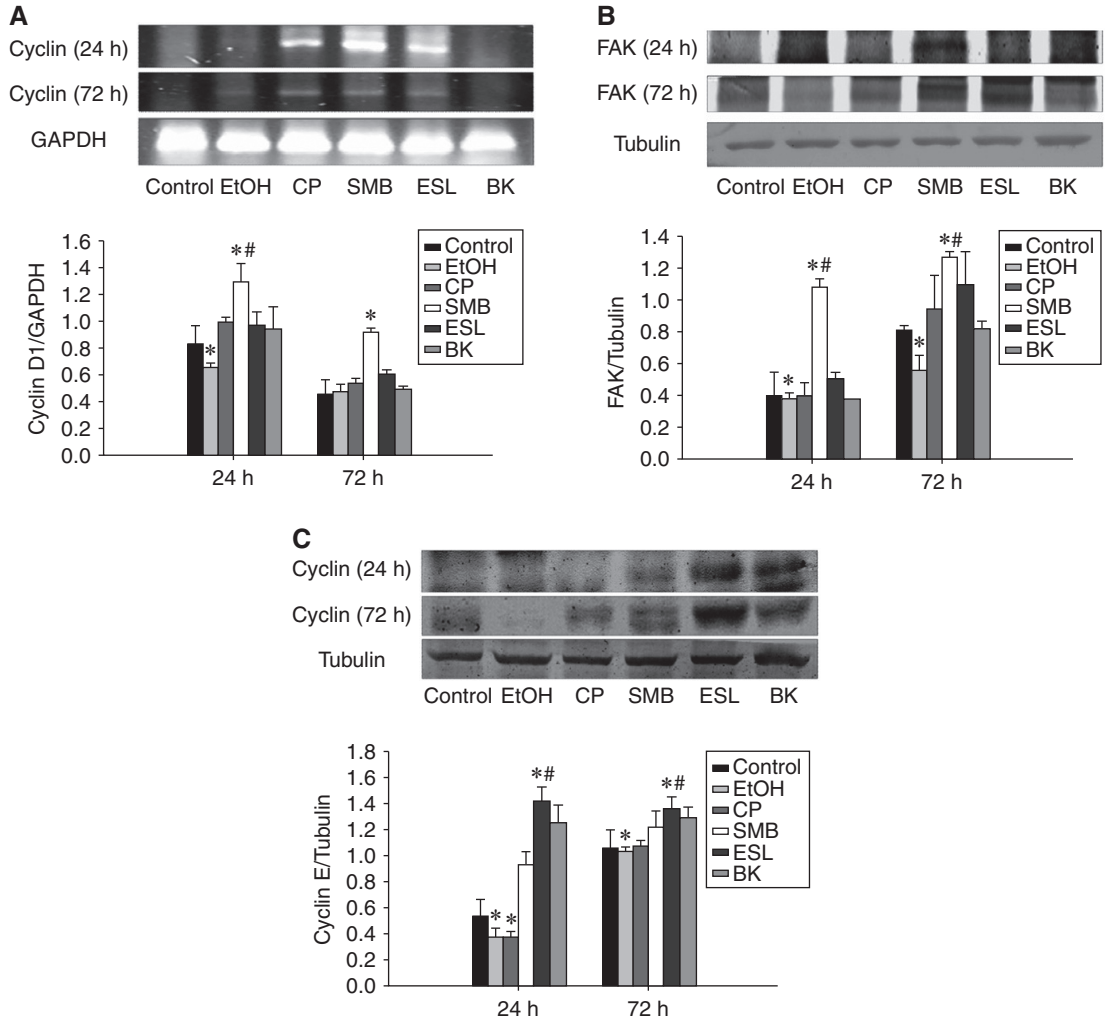

Fig. 3. Traditional Chinese medicines, *Salvia miltorrhiza Bunge* (SMB) and *Elephantopus scaber L*. (ESL), effects on fibrotic rat after 24 and 72 h post-ethanol treatment. RT-PCR analysis of Cyclin D1 mRNA expression by Traditional Chinese medicines including *Codonopsis pilosula* (CP), *Bupleurum kasi* (BK), *Elephantopus scaber L* (ESL), and *Salvia miltorrhiza Bunge* (SMB) (A). Western blotting analysis of FAK and Cyclin E expression levels by Traditional Chinese medicines including *Codonopsis pilosula* (CP), *Bupleurum kasi* (BK), *Elephantopus scaber L* (ESL), and *Salvia miltorrhiza Bunge* (SMB) (B). Equal amounts of lysate were separated by 12.5% SDS-PAGE. Quantification of protein levels densitometry analysis. All data are presented as means ± SD (n=6) $*P < 0.05$, significant difference compared with the corresponding control group. $^{\#}P < 0.05$, significant difference compared with EtOH group.

24 and 72 h (Fig. 3C) ($P < 0.05$).

Salvia miltiorrhizae Bunge (SMB) Affords Protection against Ethanol Induced ECM Degradation in Fibrotic Liver

At liver fibrosis onset increased matrix metalloproteinases (MMPs) and tissue inhibitors of metalloproteinases (TIMPs) expression plays a major role in dynamic ECM modifications. We found that *Salvia miltiorrhizae Bunge* (SMB) reduced gelatinase, matrix metalloproteinases (MMP-2) and matrix metalloproteinases (MMP-9), mRNA activities after 24 and 72 h ($P < 0.05$) (Fig. 4A). MMP-2 and MMP-9 mRNA expression were increased by ethanol contributing to fibrosis ($P < 0.05$). However, we found that TIMPs mRNA activities were increased by *Codonopsis pilosula* (CP) ($P < 0.05$) after 24 h post ethanol treatment. It is important to note that CP induction by *Codonopsis pilosula* was greater than that produced by *Salvia miltiorrhizae Bunge* (SMB) (Fig. 4B) ($P < 0.05$).

Fibrotic Liver Regeneration after PHx

Rats subjected to PHx showed significant changes in hepatocyte architecture during the first 24 h after surgery (Fig. 5). However, liver regeneration from 24 to 168 h following PHx exhibited enlarged liver mass and liver regeneration index (Figs. 5C and 5D).

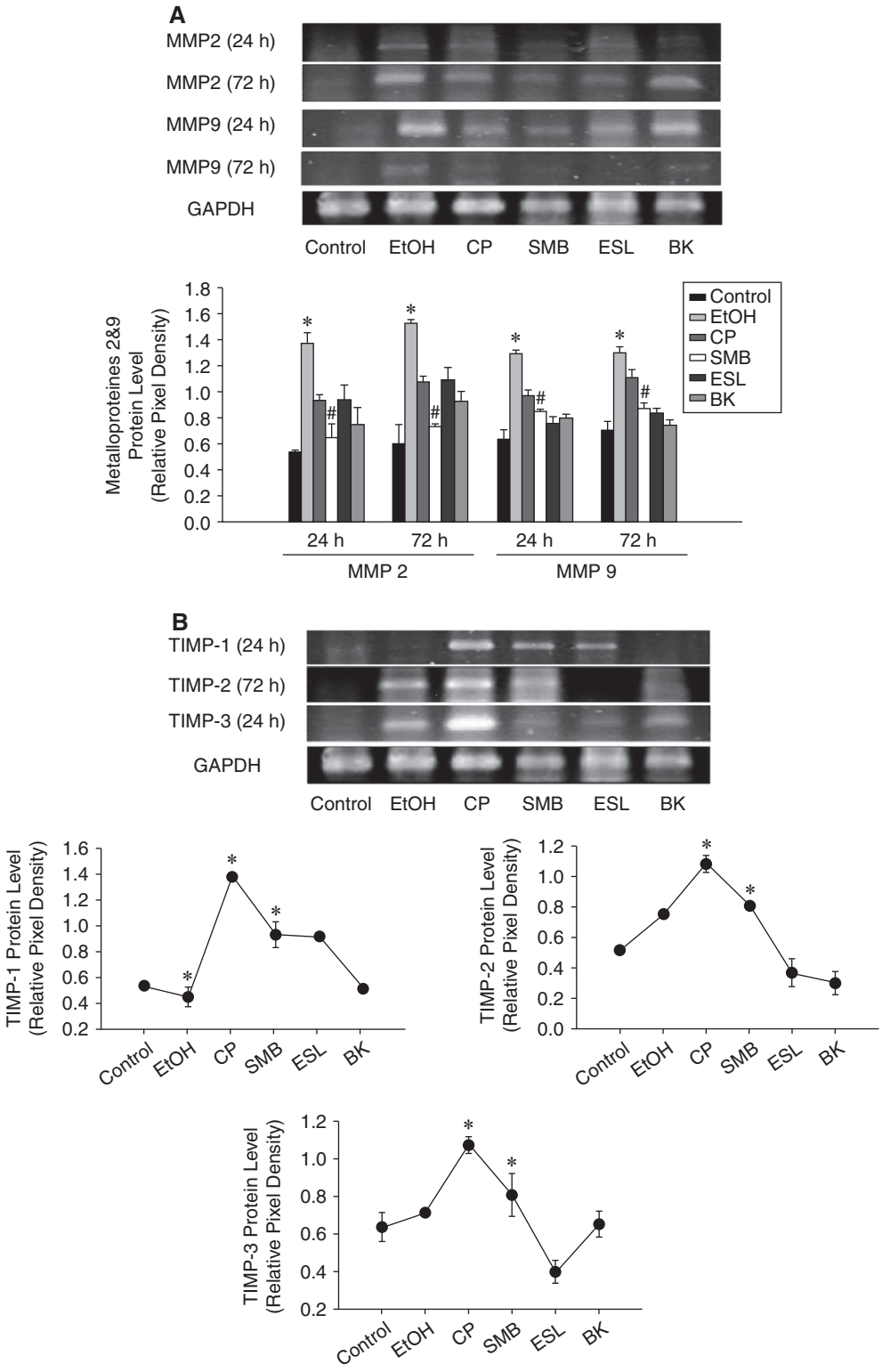

Fig. 4. Traditional Chinese medicines effect on gelatinases, MMP-2 and MMP-9, and TIMPs protein amount in the fibrotic liver. RT-PCR analysis of MMP-2 and MMP-9 mRNA expression levels by Traditional Chinese medicines including *Codonopsis pilosula* (CP), *Bupleurum kasi* (BK), *Elephantopus scaber L* (ESL), and *Salvia miltorrhiza Bunge* (SMB). after 24 h and 72 h ethanol-treated (A). RT-PCR analysis of TIMP-1, TIMP-2 and TIMP-3 mRNA expression levels by Traditional Chinese medicines including *Codonopsis pilosula* (CP), *Bupleurum kasi* (BK), *Elephantopus scaber L* (ESL), and *Salvia miltorrhiza Bunge* (SMB) after 24 h ethanol-treated (B). Equal amounts of lysate were separated by 12.5% SDS-PAGE. Quantification of densitometry analysis of protein levels. All data are presented as means ± SD (n = 6) $^{*}P < 0.05$, significant difference compared with the corresponding control group. $^{\#}P < 0.05$, significant difference compared with EtOH group.

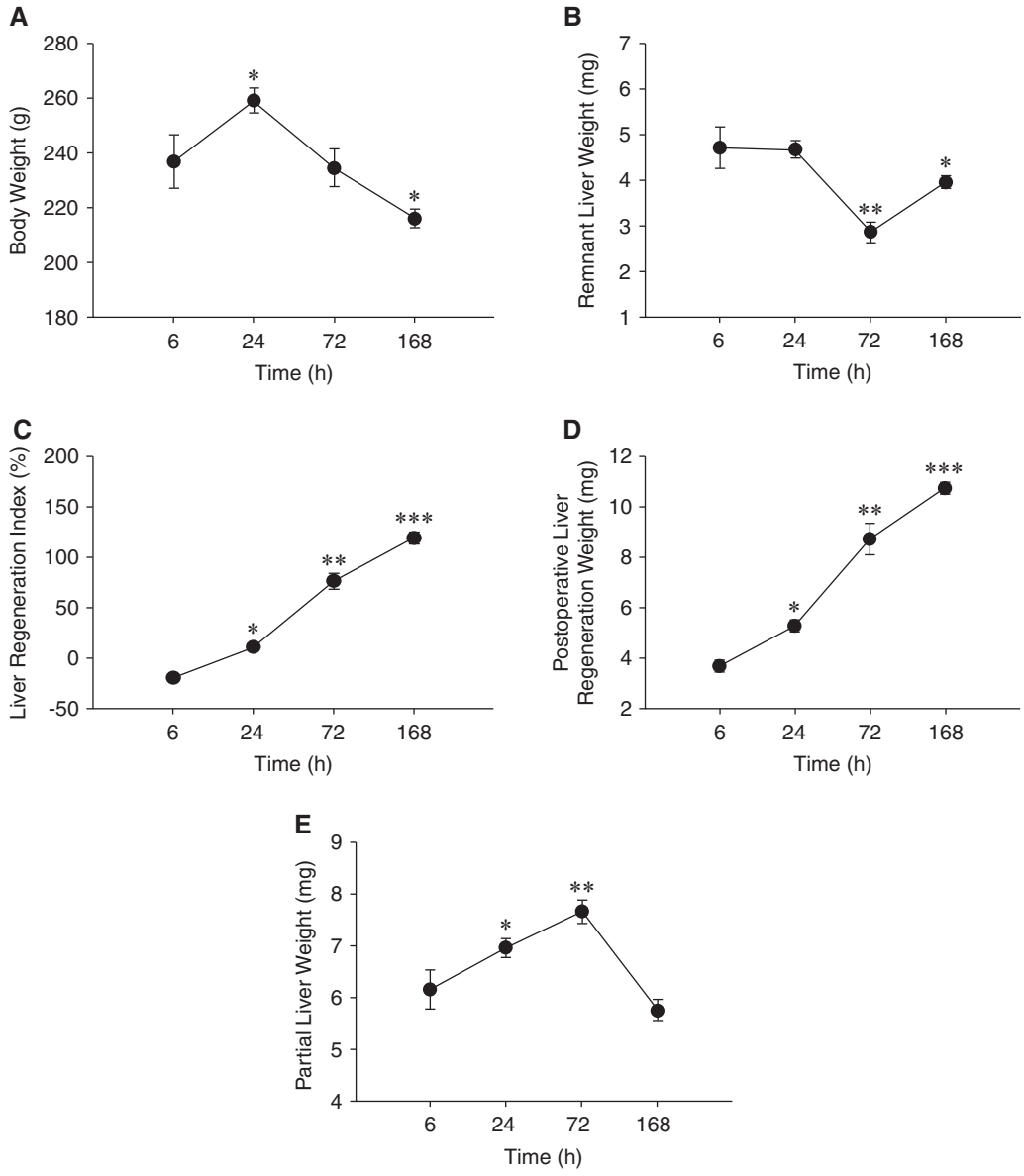

Fig. 5. Liver regeneration (%) in fibrotic rat. Body weight (A). Remnant liver weight (B). postoperative regeneration weight (C). Liver regeneration index (%) (D). Quantification of densitometry analysis of protein levels. All data are presented as means ± SD (n = 6) *$P < 0.05$, **$P < 0.01$, ***$P < 0.001$, significant difference compared with the corresponding control group.

Fig. 5, shows that the liver regeneration index (%) increased at 24 (P <0.05), 72 ($P < 0.01$), and 168 h PHx ($P < 0.001$) compared with 6 h post-surgery. Therefore, liver regeneration did occur after partial hepatectomy, even in fibrotic or cirrhotic livers.

Elephantopus scaber L. *(ESL) Induced Endogenous Cytokine, TGF-β1, mRNA Expression in Fibrotic Rats Liver Regeneration after Partial Hepatectomy*

During partial liver hepatectomy the organ attempts to repair the injury site by producing internal scar tissue as quickly as possible. *Elephantopus scaber L.* (ESL), a traditional Chinese medicine, reduced transforming growth factor beta 1 (TGF-β1) mRNA activity in fibrosis livers 24 to 168 h following PHx. *Salvia miltiorrhizae Bunge* (SMB), however, showed no significant changes 24 to 168 h in fibrotic livers following PHx (Fig. 6A). We found that TGF-β1 mRNA expression increased 24 h after oral ethanol administration ($P < 0.05$) and 168 h following liver regeneration in fibrotic rats ($P < 0.01$).

Elephantopus scaber L. *(ESL) Induced DNA Synthase, Cyclin D1 mRNA Activity at 24 h Liver Fibrotic following Partial Hepatectomy*

We suggest that traditional Chinese medicines

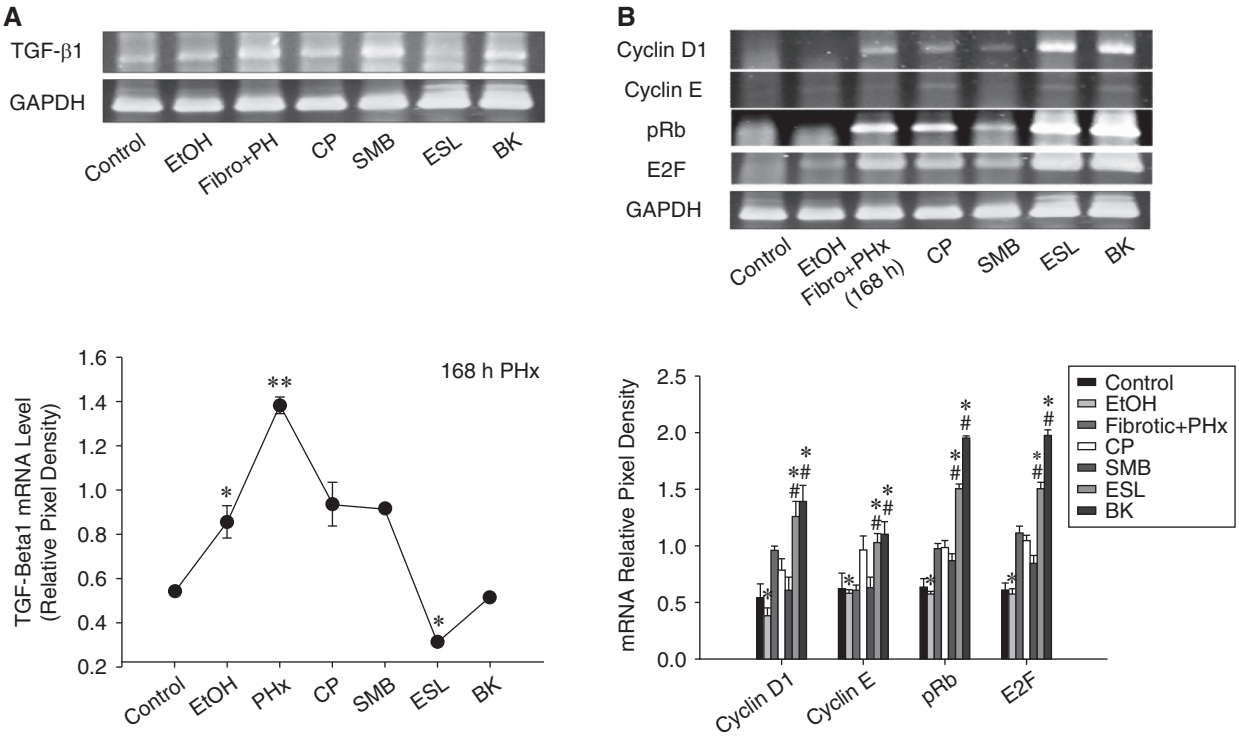

Fig. 6. A traditional Chinese medicines TGF-β1 effect on fibrotic liver after 24 h then partial hepatectomy 168 h. After 24 h ethanol-toxic injury, TGF-β1 mRNA expression in liver fibrotic following partial hepatectomy (A). After 24 h ethanol-toxic injury, Cyclin D1, Cyclin E, pRb and E2F in liver fibrotic following partial hepatectomy (B). Equal amounts of lysate were separated by 12.5% SDS-PAGE. Quantification of densitometry analysis of protein levels. All data are presented as means ± SD (n = 6) $*P < 0.05$, $**P < 0.01$, significant difference compared with the corresponding control group. $^{\#}P < 0.05$, significant difference compared with EtOH group. *Codonopsis pilosula* (CP), *Bupleurum kasi* (BK), *Elephantopus scaber L* (ESL), *Salvia miltorrhiza Bunge* (SMB), *Silymarin* (Sm).

may act as a cell cycle progression agent to make primed cells progress through the cell cycle and DNA synthesis. In the S phase Cyclin D1, Cyclin E, pRb and E2F mRNA expression by RT-PCR were increased by *Elephantopus scaber L.* (ESL) and *Buplearum kaoi* (BK) after induced liver fibrosis (Fig. 6B) ($P < 0.05$). We also found a small increase in fibrotic tissues following partial hepatectomy.

Discussion

Liver fibrosis is an alteration in chronic liver damage usually caused by alcohol and various toxins. Fibrosis to cirrhosis is the terminal stage of various liver diseases (15). However, the liver is one of the most complex organs with a potent orchestrated response regeneration capacity. In order to set the optimal mass in relationship to its liver functions the liver induces compensatory hyperplasia mechanisms (16). Previous reports indicted that herbal medicines have been used to treat liver disorders for thousands of years in the East and have now become a promising therapy internationally for pathological liver conditions (17). In the present study we presume that traditional Chinese medicines (TCMs), *Codonopsis pilosula* (CP), *Salvia miltorrhiza Bunge* (SMB), *Bupleurum Kasi* (BK), and *Elephantopus scaber L.* (ESL) may promote liver regeneration in fibrotic rats following partial hepatectomy. We are interested in the effects of traditional Chinese medicines after surgical resection to remove a tumor together with surrounding liver cirrhotic or fibrosis tissue. We compiled and discuss the molecular biological analytical method of five herbal medicines for liver protection.

We observed that *Salvia miltorrhiza Bunge* (SMB) induced HGF, FAK, Cyclin D1, and pRb protein expression in the G1 phase after liver fibrotic injury at 24 and 72 h ($P < 0.05$) (Figs. 2 and 3). However, *Elephantopus scaber L.* (ESL) induced cell cycle S phase liver regeneration after fibrotic injury. Most commonly, after the liver was injured it attempted to repair the injured site by producing internal scar tissue as quickly as possible (18). We could observe the liver producing extracellular matrix (ECM) remodeling modification. Fig. 4, shows *Salvia miltorrhiza Bunge* (SMB) prevented MMPs and TIMPs expression in fibrotic rats. Some previous research papers demonstrated that partial hepatectomy (PHx) creates a cell

cycle dependent regulation and a potential physiological role in G1 progression (19). However, we are interested in fibrotic liver tissue 24 to 168 h following partial hepatectomy ($P < 0.05$). During this time the liver cell cycle is stronger than under normal conditions. After 168 h following PHx, alcohol toxicity subsides. We found that *Elephantopus scaber L.* (ESL) and *Bupleurum Kasi* (BK) reduce TGF-β1 and enhance Cyclin D1, Cyclin E, pRb and E2F mRNA expression during liver regeneration in fibrotic rats (Fig. 6). We think that after 168 h partial hepatectomy the cell cycle transitions into the S phase. During this time different traditional Chinese medicines have different effects.

Liver cirrhosis fibrosis is a high risk factor for liver cancer. Surgery is the suggested treatment for hepatic tumor to remove the abnormal growth with the goal of preventing or arresting metastatic cancer (20). After surgery hepatocytes need to grow and maintain liver mass (21) and functions. We know that partial hepatectomy hepatocytes proliferation function cannot maintain the integrated whole liver function (22). Drugs for hepatic growth liver regeneration have been used after or during partial hepatectomy (23, 24). We suggest that traditional Chinese medicines may act as hepatoprotective agents in patients with hepatic carcinoma. It is worth noting that traditional Chinese medicines may act as hepatoprotective agents to accelerate cell cycle progress (25). Chinese medicine is currently the world's most effective treatment for liver disease (26). It has shown positive effects in treating nearly every known form of liver disease including cirrhosis (27), hepatitis, necrosis (28) and liver damage due to drug and alcohol abuse (29). That is why they are used today.

Acknowledgments

The authors who have taken part in this study have declared that they do not have anything to disclose regarding funding or conflict of interest with respect to this manuscript. This work was supported by a grant from the National Natural Science Foundation of China (No. 30760263) and Taiwan Ministry of Health and Welfare Clinical Trial and Research Center of Excellence (MOHW104-TDU-B-212-113002).

References

1. Chen, H.T., Tsai, Y.L., Chen, Y.S., Jong, G.P., Chen, W.K., Wang, H.L., Tsai, F.J., Tsai, C.H., Lai, T.Y., Tzang, B.S., Huang, C.Y. and Lu, C.Y. Dangshen (*Codonopsis pilosula*) activates IGF-I and FGF-2 pathways to induce proliferation and migration effects in RSC96 Schwann cells. *Am. J. Chin. Med*. 38: 359-372, 2010.
2. Dwivedi, Y., Rastogi, R., Sharma, S.K., Garg, N.K. and Dhawan, B.N. Picroliv affords protection against thioacetamide-induced hepatic damage in rats. *Planta. Med.* 57: 25-28, 1991.
3. Ehrenfried, J.A., Ko, T.C., Thompson, E.A. and Evers, B.M. Cell cycle-mediated regulation of hepatic regeneration. *Surgery* 122: 927-935, 1997.
4. Fausto, N. and Webber, E.M. Control of liver growth. *Crit. Rev. Eukaryot. Gene Expr.* 3: 117-135, 1993.
5. Fausto, N. Liver regeneration. *J. Hepatol*. 32: 19-31, 2000.
6. Geetha, B.S., Latha, P.G. and Remani, P. Evaluation of Elephantopus scaber on the inhibition of chemical carcinogenesis and tumor development in mice. *Pharm. Biol.* 48: 342-348, 2010.
7. Hashimoto, M. and Watanabe, G. Functional restoration of cirrhotic liver after partial hepatectomy in the rat. *Hepatogastroenterology* 52: 897-902, 2005.
8. Kim, D.W., Chung, H.J., Nose, K., Maruyama, I. and Tani, T. Preventive effects of a traditional Chinese formulation, Chaihu-jia-Longgu-Muli-tang, on intimal thickening of carotid artery injured by balloon endothelial denudation in rats. *J. Pharm. Pharmacol.* 54: 571-575, 2002.
9. Kountouras, J., Boura, P. and Lygidakis, N.J. Liver regeneration after hepatectomy. *Hepatogastroenterology* 48: 556-562, 2001.
10. Lapis, K., Jeney, A., Divald, A., Vajta, G., Zalatnai, A. and Schaff, Z. Experimental studies on the effect of hepatoprotective compounds. *Tokai J. Exp. Clin. Med.* 11 Suppl: 135-145, 1986.
11. Li, M.N., Dong, W.B., Cao, M., Deng, C.L. and Wang, M.Y. Role and mechanism of Salvia miltiorrhiza Bunge in alleviating injury induced by hypoxia/reoxygenation in HK-2 cells. *Zhongguo Dang Dai Er Ke Za Zhi* 9: 559-562, 2007.
12. Lin, C.C., Tsai, C.C. and Yen, M.H. The evaluation of hepatoprotective effects of Taiwan folk medicine 'teng-khia-u'. *J. Ethnopharmacol*. 45: 113-123, 1995.
13. Michalopoulos, G. HGF and liver regeneration. *Gastroenterol. Jpn.* Suppl 4: 36-9, discussion 53-56, 1993.
14. Michalopoulos, G.K. and DeFrances, M.C. Liver regeneration. *Science* 276: 60-66, 1997.
15. Oberhammer, F.A., Pavelka, M., Sharma, S., Tiefenbacher, R., Purchio, A.F., Bursch, W. and Schulte-Hermann, R. Induction of apoptosis in cultured hepatocytes and in regressing liver by transforming growth factor beta 1. *Proc. Natl. Acad. Sci. USA* 89: 5408-5412, 1992.
16. Peng, R., Wei, Y., Wang, A., Wu, X. and Li, L. [Characteristics of element contents and their influence factors in Codonopsis tangshen]. *Zhongguo Zhong Yao Za Zhi* 34: 1335-1338, 2009.
17. Ping, C., Lin, Z., Jiming, D., Jin, Z., Ying, L., Shigang, D., Hongtao, Y., Yongwei, H. and Jiahong, D. The phosphoinositide 3-kinase/Akt-signal pathway mediates proliferation and secretory function of hepatic sinusoidal endothelial cells in rats after partial hepatectomy. *Biochem. Biophys. Res. Commun.* 342: 887-893, 2006.
18. Pradhan, S.C. and Girish, C. Hepatoprotective herbal drug, silymarin from experimental pharmacology to clinical medicine. *Indian J. Med. Res.* 24: 491-504, 2006.
19. Ren, Z.H., Tong, Y.H., Xu, W., Ma, J. and Chen, Y. Tanshinone II A attenuates inflammatory responses of rats with myocardial infarction by reducing MCP-1 expression. *Phytomedicine* 17: 212-218, 2010.
20. Rosa, H., Parise, E.R., Paranhos, F.R., Braga, A.L., Freitas, A.S., Hidalgo, A.N. and Mor, M.B. Controlled production of cirrhosis in the rat liver. *Arq. Gastroenterol.* 28: 39-43, 1991.
21. Skrtic, S., Wallenius, K., Sjögren, K., Isaksson, O.G., Ohlsson, C. and Jansson, J.O. Possible roles of insulin-like growth factor in regulation of physiological and pathophysiological liver growth. *Horm. Res.* (Suppl 1) 55: 1-6, 2001.
22. Su, M., Chung, H.Y. and Li, Y. Deoxyelephantopin from Elephantopus scaber L. induces cell-cycle arrest and apoptosis in the human nasopharyngeal cancer CNE cells. *Biochem. Biophys. Res. Commun.* 411: 342-347, 2011.
23. Tian, R.T., Xie, P.S. and Liu, H.P. Evaluation of traditional Chinese herbal medicine: Chaihu (Bupleuri Radix) by both high-perfor-

mance liquid chromatographic and high-performance thin-layer chromatographic fingerprint and chemometric analysis. *J. Chromatogr. A.* 1216: 2150-2155, 2009.

24. Wang, L., Xu, M.L., Hu, J.H., Rasmussen, S.K. and Wang, M.H. Codonopsis lanceolata extract induces G0/G1 arrest and apoptosis in human colon tumor HT-29 cells--involvement of ROS generation and polyamine depletion. *Food Chem. Toxicol.* 49: 149-154, 2011.
25. Wu, J.W., Lin, L.C., Hung, S.C., Lin, C.H., Chi, C.W. and Tsai, T.H. Hepatobiliary excretion of silibinin in normal and liver cirrhotic rats. *Drug Metab. Dispos.* 36: 589-596, 2008.
26. Yamanaka, N., Okamoto, E., Kawamura, E., Kato, T., Oriyama, T., Fujimoto, J., Furukawa, K., Tanaka, T., Tomoda, F. and Tanaka, W. Dynamics of normal and injured human liver regeneration after hepatectomy as assessed on the basis of computed tomography and liver function. *Hepatology* 18: 79-85, 1993.
27. Yen, M.H., Weng, T.C., Liu, S.Y., Chai, C.Y. and Lin, C.C. The hepatoprotective effect of Bupleurum kaoi, an endemic plant to Taiwan, against dimethylnitrosamine-induced hepatic fibrosis in rats. *Biol. Pharm. Bull.* 28: 442-448, 2005.
28. Zarnegar, R., DeFrances, M.C., Kost, D.P., Lindroos, P. and Michalopoulos, G.K. Expression of hepatocyte growth factor mRNA in regenerating rat liver after partial hepatectomy. *Biochem. Biophys. Res. Commun.* 177: 559-565, 1991.
29. Zhang, Y., Wei, R.X., Zhu, X.B., Cai, L., Jin, W. and Hu, H. Tanshinone IIA induces apoptosis and inhibits the proliferation, migration, and invasion of the osteosarcoma MG-63 cell line *in vitro*. *Anticancer Drugs* 23: 212-219, 2012.